

Dysfunction of locomotion after resection of the meniscus based on three-dimensional motion analysis

KATARZYNA OGRODZKA, WIESŁAW CHWAŁA, TADEUSZ AMBROŹY

Academy of Physical Education, Cracow

The three-dimensional analysis of the locomotion was carried out in a patient after resection of the medial meniscus in the left knee joint, using Vicon system. Examinations were performed two times. On the basis of the first examination an intensive three-month physiotherapy was planned and carried out. Angular changes of lower limb joints and changes of length of the selected muscles were taken into consideration.

Key words: three-dimensional motion analysis, locomotion, meniscus

1. Introduction

Among many injuries one of the most dangerous for athletes is the injury to the meniscus [3]. It has an influence on normal gait phases. It usually occurs suddenly, mainly in football players, skiers, athletes and followers of the combat training as a result of rotary movement of lower limb when the knee is flexed or as a result of total small microinjuries and recurrent overloads [5]. The greater the force of the rotary movement of the lower limb, the more serious the injury to the knee joint. Also sudden rotary movement of the trunk in relation to fixed and flexed knee can cause meniscus injuries [4].

If the force vertically weighs down the knee during rotation of the lower extremity, the injury to the meniscus is located in its front or back part. If the knee joint is bent strongly, the line of the injury runs in the back part of the meniscus, and if the bend is slight the injury is in the front part of the meniscus. For the reason of the anatomical constitution, the medial meniscus is more often torn apart than the lateral one [6].

2. Material and method

The three-dimensional analysis of the locomotion was carried out in a patient after resection of the medial meniscus in the left knee joint, using Vicon system [1], [2]. The patient being examined was the follower of the combat training with high qualifications and long (30 years) training. First examination was performed in May 2003. It included registration of the gait with natural speed. We chose 15 cycles with stabilized speed for the analysis. This allowed us to describe the range of dysfunction in each gait phase which was the result of loosing the shock absorption function of the left knee joint after resection of the meniscus. Angular changes of the lower limb joints and the changes of length of selected muscles were taken into consideration. The results of the examination were shown against the background of physiological gait parameters of 80 healthy people whose age was between 25 and 45 years.

On the basis of the first examination an intensive three-month physiotherapy was planned and carried out. The main goal of the physiotherapy was to increase the strength of the quadriceps, thereby to decrease the disorder in normal gait cycle. At the same time patient was subjected to cryotherapy, which accelerated the process of regeneration and treatment. The rehabilitation conducted was based on isometric exercises of the quadriceps, active exercises "with load" and exercises which took advantage of synergisms. Both time and intensity of the exercises were raising gradually.

Next analysis of the locomotion was performed after physiotherapy (in July 2003). It showed the differences between the values of kinetic gait parameters before and after rehabilitation.

3. Result and discussion

The first examination of ankle joint showed a significant lengthening of stance phase in both limbs, about 10° over the norm in sagittal plane, and shortening of swing phase. There was also no plantar flexion in swing phase. After rehabilitation the results of angular changes were similar to the norm (figure 1).

There was a slight increase of flexion (about 8°) in terminal stance in the range of knee function of sagittal plane in operated limb. The next examination demonstrated a minimal lengthening of the stance phase and an increased flexion in the healthy limb during weight bearing (about 14°) (figure 2).

Significant changes, above the norm, towards varus knee in stance phase occurred in the frontal plane in the first examination of the operated knee joint. In an initial contact, the differences approached 3° compared to the biomechanical norm. After rehabilitation these differences decreased by about 1° and since then the terminal stance phase parameters have fulfilled the norm (figure 3).

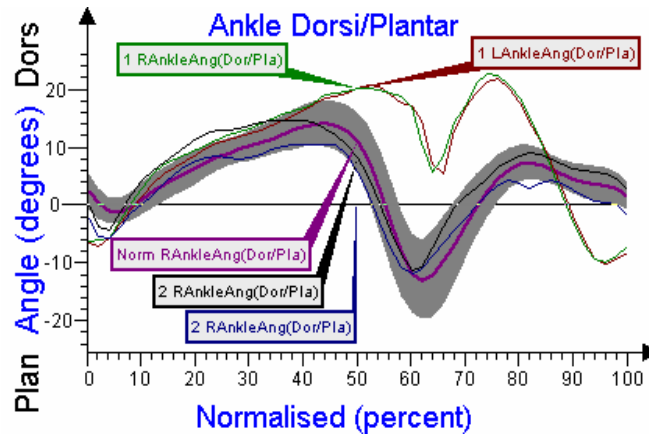


Fig. 1. Angular changes of the ankle joints in sagittal plane

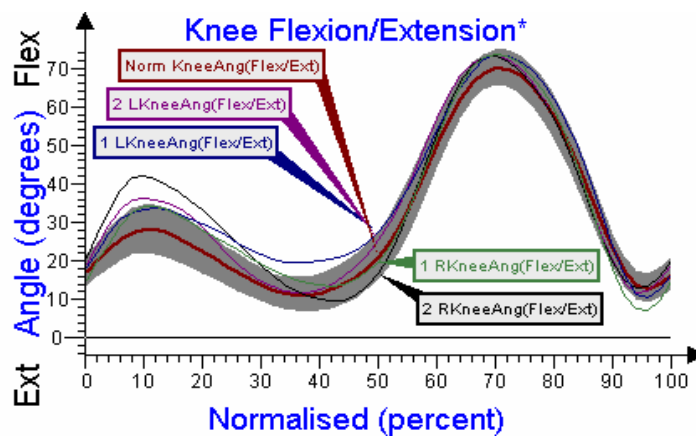


Fig. 2. Angular changes of the knee joints in sagittal plane

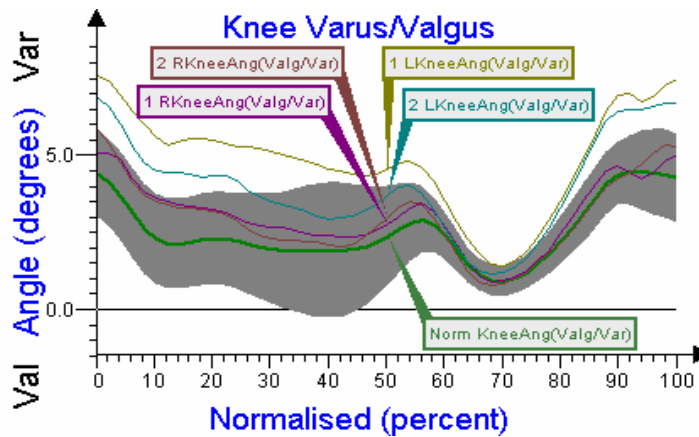


Fig. 3. Angular changes of the knee joints in the frontal plane

Angular changes in operated knee joint in the horizontal plane were characterized by large displacement towards internal rotation. Maximum of the rotation angle was 6.5° in swing phase. In the second examination, an increased rotation was still visible, but the range of motion was similar to the norm (figure 4).

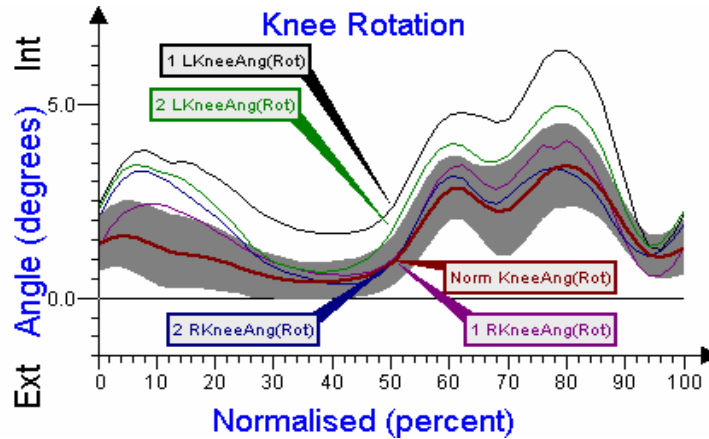


Fig. 4. Angular changes of the knee joints in the horizontal plane

There was also a noticeable projection of dysfunction on the hip joint in sagittal plane. There was no physiological hyperextension in operated limb in terminal stance. The differences approach 17° compared to the norm. After rehabilitation the parameters analyzed were similar to the norm (figure 5).

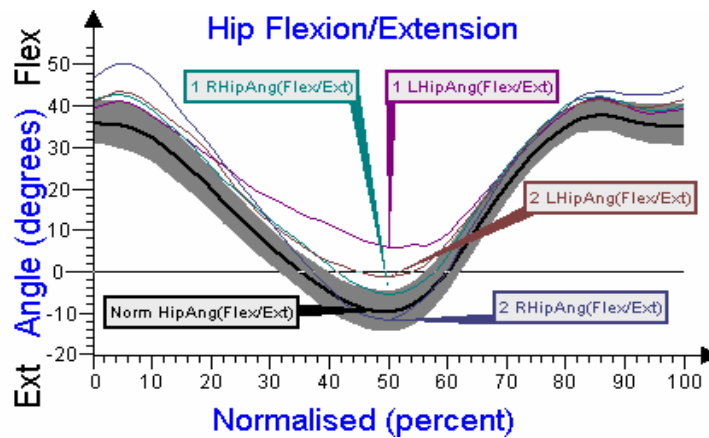


Fig. 5. Angular changes of the hip joints in sagittal plane

There was also an evident over-norm change in the length of the lateral head of the gastrocnemius muscle in the healthy limb. Due to the absence of plantar flexion in the

ankle joint and two combined functions of its muscle, its large lengthening in a whole gait cycle shows the compensating function of this limb. The concentric contraction in a plantar flexion is decreased by about 28 mm in terminal stance. There was no improvement in the functioning of the muscle after rehabilitation. The operated limb proved a normative character of the muscle length changes before and after the treatment (figure 6).

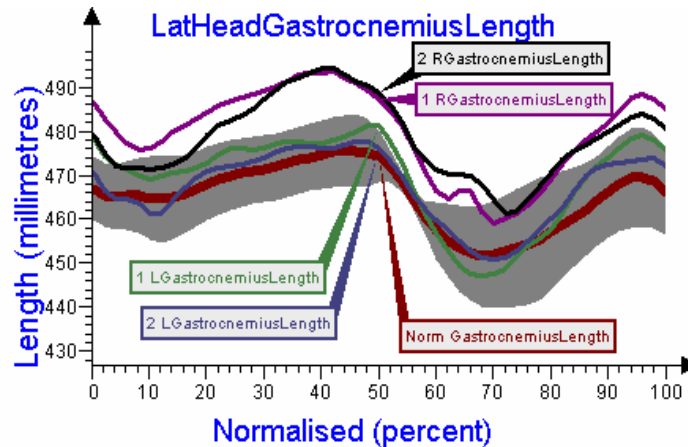


Fig. 6. Length changes of the lateral head of the gastrocnemius muscle

4. Conclusions

1. A partial loss of shock absorbing function after resection of meniscus of the knee joint has an influence on normal gait pattern, causing deviations from biomechanical norms in the range of the angular changes in knee, ankle and hip joints in both extremities.

2. The highest dysfunction occurs in the range of angular changes of the knee joint in frontal and horizontal planes of the operated limb.

3. There is also a noticeable compensating work of the healthy limb in the form of an excessive elongation of the gastrocnemius muscle in the gait cycle.

4. After intensive physiotherapy the gait pattern was similar to the biomechanical norm.

References

- [1] ALLARD P., CAPPOZZO A., LUNDBERG A., VAUGHAN C.L., *Three-Dimensional Analysis of Human Locomotion*, Wiley and Sons, New York, 1997.
- [2] ALLARD P., STOKES I.A.F., BLANCHI J.P., *Three-Dimensional Analysis of Human Movement*, Human Kinetics, New York, 1995.

- [3] BOBER T., *Biomechanika chodu i biegu*, AWF, Wrocław, 1985.
- [4] DZIAK A., TAYARA S., *Urazy i uszkodzenia w sporcie*, Wydawnictwo Kasper, Kraków, 2000.
- [5] GARLICKI J., KUŚ W.M., *Traumatologia sportowa*, PZWL, Warszawa, 1978.
- [6] GRUCA A., TYLMAN D., DZIAK A., *Chirurgia ortopedyczna*, Vol. III, PZWL, Warszawa, 1993.
- [7] PERRY J., *Gait analysis*, Thorofare, SLACK, 1992.