

Influence of cementless cup surface on stability and bone fixation 2 years after total hip arthroplasty

WIKTOR URBAŃSKI, ARTUR KRAWCZYK, SZYMON Ł. DRAGAN,
MIROSLAW KULEJ, SZYMON F. DRAGAN*

Department and Clinic of Orthopaedic and Traumatologic Surgery, Wrocław Medical University, Poland.

Loss of fixation between bone and implant surface is one of the main treatment problems in total hip arthroplasty. It might lead to implant instability, bone loss and treatment failure resulting in revision surgery. Surface modification is a method for improving bone response to implant and increasing implant osseointegration. However, the currently applied modifications such as hydroxyapatite coatings do not meet expectation and do not provide good clinical result.

The object of the study was to evaluate the influence of acetabular cup surface modification on fixation and bone remodelling in total hip arthroplasty. Clinical and radiological outcomes were evaluated in patients two years after cementless total hip replacement. Two groups were compared: patients with acetabular component with uncoated titanium surface and patients with hydroxyapatite-coated acetabular surface. Hips X-rays were analysed for early signs of losing stability of acetabular cups. Two years after surgery the analysis of X-rays did not reveal any statistical differences in stability, migration of acetabular components of endoprosthesis between both groups. No differences were also observed in bone remodelling around implants. Particularly high percentage of cups, i.e. 17.64%, were classified into the group with high risk of early implant loosening, i.e., the group with HA coatings. Hydroxyapatite coatings on titanium cementless acetabular cups implanted by *press-fit* technique have no influence on their stability, bone-implant fixation and the remodelling of bone surrounding an implant two years after surgery.

Key words: implant surface, acetabular cup, total hip arthroplasty, osseointegration, bone fixation, implant loosening

1. Introduction

Total hip arthroplasty (THA) became one of the most popular procedure in orthopaedic surgery and the number of patients requiring THA continuously increase due to demographic changes and life style trends. Regardless of huge clinical success of THA, the procedure is not free of complication and has some limitations. Modern anaesthesiology, programs of antibiotic and antithrombotic prophylaxis and progress in surgical technique significantly decreased the number of early complications but late complications still have occurred [1]. Among them the most important is aseptic implant loosening [2]. It is a main cause

of THA treatment failure – 70% of all revision procedures of THA and 44% of total knee arthroplasty (TKA) are caused by aseptic loosening [3], [4].

Aseptic loosening is (a primary or secondary) loss of implant fixation in bone, its instability and even implant migration caused mainly by biomechanical impairment or low implant surface biocompatibility and osteoconductivity. Cemented endoprosthesis fixation is based on pure mechanical manners [5], cementless implant is supposed to create chemical and biological binding with host tissues [6]. A full understanding of osseointegration (first described by Branemark), exploration of bone-implant reactions might help to improve clinical performance of implants. These processes directly depend on biomaterial surface

* Corresponding author: Szymon F. Dragan, Department and Clinic of Orthopaedic and Traumatologic Surgery, Wrocław Medical University, ul. Borowska 213, 50-556 Wrocław, Poland. Tel: +48-71-734-32-00, e-mail: szymondragan@wp.pl

Received: January 4th, 2012

Accepted for publication: March 29th, 2012

properties. The construction of new biomaterials and modification of their surfaces are crucial for the improvement of their physicochemical, mechanical and biological interactions, leading to successful and permanent implant integration with bone tissue. Biomaterial surface modification, e.g., changing surface topography, chemical composition or addition of biologic compounds [42], is a method for achieving those goals.

Creating rough or porous coatings on the surface of implant used in THA is a very common procedure. The synthesis of a thin layer on an implant surface (composite) is a method for eliminating some disadvantages of both materials and maintaining their advantages. Porous calcium phosphate- or hydroxyapatite (HA)-based ceramic materials are known for their good biocompatibility and osteoconductivity; nevertheless, the usage of these biomaterials alone in weight bearing applications is not possible because of their rigidity and fragility. However, coating a metallic implant with HA layer enables us to improve biomaterial osteoconduction and to maintain anticipated metal mechanical properties. Recent years have brought more and more data that HA coatings do not fulfil expectations. This is mainly due to poor durability of the coatings which are destroyed by cell resorption (macrophage and osteoclast activity), mechanical factors (mechanical abrasion), dissolving and delamination.

The analysis of clinical and radiological results of patients after THA enables us to identify changes in

bone tissue which lead to acetabular cup loosening [1], [9]. Roentgenometric analysis can prove cup stable fixation or instability and migration. As other authors reported earlier, to evaluate bone remodeling around implant it is crucial to evaluate bone density and also to analyse qualitatively bone tissue (e.g., osteolysis, osteosclerosis, bone-implant interface) [10]–[16].

The aim of this study was to assess the influence of acetabular cup surface modification on fixation and bone remodelling in cementless total hip arthroplasty based on X-ray analysis and clinical results of patients 2 years after implantation.

2. Material and methods

32 patients (32 hips) were treated with cementless THA in the Department of Orthopaedic Surgery and Traumatology of Wrocław University Hospital. The patients were divided into two groups, depending on the acetabular cup surface: 1) patients with titanium cups and porous hydroxyapatite (HA)-coated cups, 17 endoprostheses, 2) patients with titanium implants and porous uncoated surfaces (without HA), 15 endoprostheses (table 1). The patients with hydroxyapatite-coated cups were divided into two subgroups, depending on the type of articulation: steel–polyethylene

Table 1. Acetabular cups evaluated in the study

Implant surface	Trade names of acetabular cups and their surface characteristics	Number of assessed cups	
Uncoated	Duraloc (DePuy, Johnson & Johnson). Spherical titanium cup coated with porous pure titanium layer for better bone fixation and subsequent osseointegration. The layer called “Porocoat Porous Coating” is formed by sintering beads of titanium and form a porous surface, with an average pore size of about 250 µm [16].	8	15 (49%)
	Plasmacup (Aesculap, Braun). “Pure titanium” (Ti/ISO 5832-2) particles are applied to the cup surface with “vacuum coating” method, creating porous surface. This layer is called “Plasmapore”. It is 0.35 mm thick, its microporosity reaches 40% and pore size ranges from 50 to 200 µm. The rest of the acetabular component is made of a Ti6Al4V alloy (ISOTAN®F, ISO 5832-3) [17].	7	
Hydroxyapatite-coated	Trident (Stryker). On the cup surface porous layer of pure titanium (arc deposition method), with an average porosity of 72% with additional hydroxyapatite coating, layer thickness of about 50 microns. No details available about the method of layer synthesis. Surface modification called <i>PureFix HA</i> [18].	6	17 (51%)
	Ringloc (Biomet). Semi-spherical titanium (Ti4Al6V) cup with surface coated with porous pure titanium and hydroxyapatite (“Plasmapatita”) by plasma spray method [19].	9	
	Duraloc Option Cup (DePuy, Johnson and Johnson). Titanium semi-spherical cups with the surface coated with aforementioned “Porocoat Porous Coating” and then coated with 35 micron thick hydroxyapatite [17].	1	

articulation (6 implants) and ceramics–ceramics articulation (11 implants).

An average age of patients was 55 years, 20 women and 10 men. THA was performed in 16 patients, mostly because of primary osteoarthritis; in 10 patients due to secondary osteoarthritis caused by developmental dysplasia of hip (DDH); and in 4 patients suffering from avascular necrosis of femoral head (AVN).

To standardize biomechanical conditions in all patients with screw cups, any additional stabilisation (screws, pegs) were excluded. Only true press-fit implants were evaluated. Patients with short and classic stems were included. Severe primary deformity of hips, low bone quality and bone loss were also the criteria of exclusion from the experiment. Patients with infections and patients unable to walk did not participate in the experiment.

Functional hip examination and X-ray pictures were evaluated to determine the results of THA. The X-ray studies conducted 3–5 days after surgery and two years after the surgery were compared.

2.1. Functional assessment

Two years after THA patients were examined in outpatient clinic. Based on the Harris Hip Score (HHS) [21], [22] we assumed the following results: excellent, from 90 to 100 points; good, from 80 to 89 points; satisfactory, from 70 to 79 points; bad, below 70 points.

2.2. X-ray assessment

Radiographs of hip joints in antero-posterior projections (AP) were taken by Siemens digital X-ray for patients lying under standard conditions. X-ray tube distance from the hip examined was 0.95 m. Based on the evaluation of radiographs, we determined the stability of acetabular cups, implant–bone fixation (the method described by Engh), the remodelling of bone surrounding a cup in DeLee–Charnley zones [23].

Acetabular cup fixation parameters were evaluated based on the methods described in the literature [10]–[15] and using the K-PACS (Software version V1.6.0). On the frontal plane, horizontal and vertical migration of cups were determined. The authors assumed that a change of cup inclination angle of at least 3° and any parameter value of 2 mm or more indicates cup instability. Changing the angle of 5° and any distance parameter value at least 4 mm give evidence of instability (figure 1).

The implant–bone fixation was assessed according to modified criteria of ENGH et al. [15], MASSIN et al. [16] and MANLEY et al. [24] distinguishing between three types of bonding:

I. Stable fixation with bone ingrowth (osseointegration). No radiolucent lines extending across 50% or more of any DeLee and Charnley zone and there was no measurable migration of the component.

II. Stable fixation with fibrous ingrowth if radiolucent lines were present in all three zones but

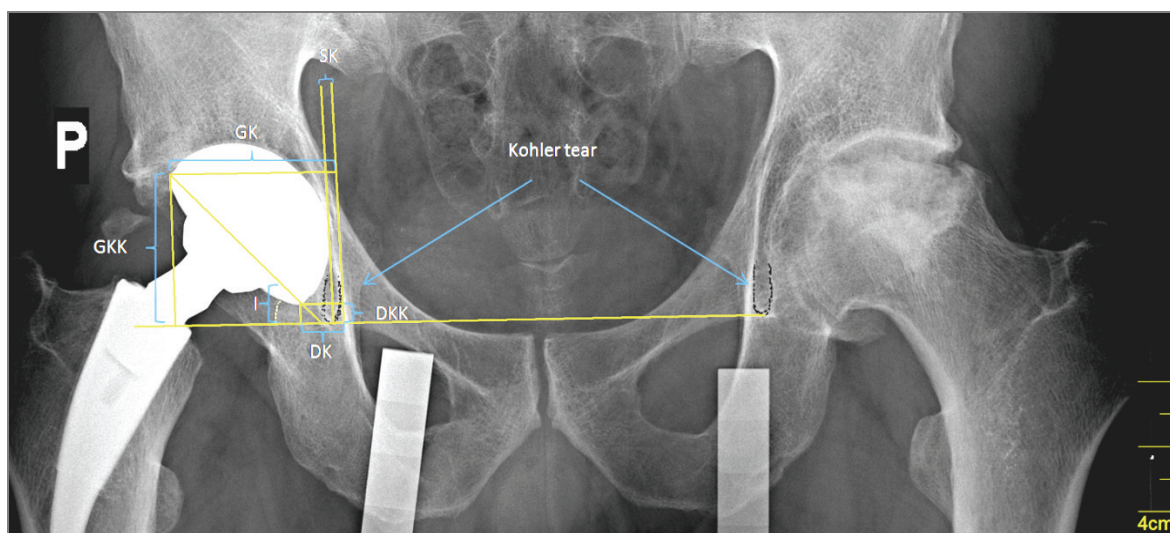


Fig. 1. Acetabular cup position parameters on X-ray.

I – inclination angle, SK – Kohler line–cup tangent vertical line distance,
 DKK – lower cup margin–both Kohler tears line distance,
 GKK – upper cup margin–both Kohler tears line distance,
 GK – upper margin–Kohler tear distance, DK – lower cup margin–Kohler tear distance

the component had not migrated – measurement change not greater than 4 mm and 5° inclination angle.

III. Unstable. Radiolucent lines in all three zones were present and the cup had migrated more than 4 mm.

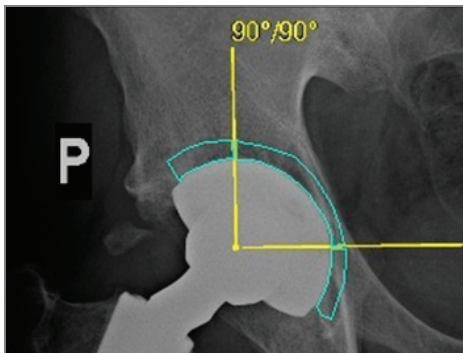


Fig. 2. Pixel intensity (PI) measurement of bone tissue surrounding implant in DeLee–Charnley zones. White curved lines mark the area analysed

Average pixel intensity was measured using 3D Doctor software. Bone area was analysed up to 0.5 cm from the implant. The method is based on gray pixel brightness scale whose range extends from 0 to 255, where 0 is completely black image, while 255 is completely white area (figure 2).

3. Results

3.1. Functional assessment

According to HHS, the functional assessment scale, one patient's result was satisfactory (77 points), in three cases a good outcome was achieved, while the rest of the patients reported an excellent result. However, the differences between groups were small and did not reach statistical significance levels in any of the parameters assessed (table 2).

No significant differences were noticed in HHS scale between endoprostheses with polyethylene/steel and ceramic/ceramic articulations (table 3).

3.2. X-ray assessment

2 years after implantation the change of measuring value, compared to the beginning, in most cases (93.75% for SK, 90.62% for DK, 90.62% for DKK, 65.62% for GKK) did not exceed 2 mm, and usually it approached 1 mm. Mostly these differences were not statistically significant, with the exception of the distance measured from the bottom edge of the cup to the Kohler lines (DKK) in HA-coated cups and the inclination angle in cups without HA (*t*-test *p*-value more than 0.05) (table 4).

If the changes of measuring values were observed the authors noticed that directions of migrations were similar in most cases. Migrated cups went valgus – the angle of inclination (I) increased (only in five cases decreased), migrated to the midline – parameters determining horizontal stability as DK, SK, GK decreased (except for 4 cases), and migrated upwards – measurements of GKK, DKK increased.

Comparison of changes (Δ – primary X-ray and two years after implantation) for each measurement between hydroxyapatite-coated cups and uncoated cups revealed the differences in values' changes (greater in the group with HA) but no statistic significance was proved.

Comparison of measuring changes between patients with polyethylene/steel and ceramics/ceramics articulations revealed that three measurements: I, DK, and GKK had higher average cup migration in polyethylene articulation than in ceramic one. However, only change of the inclination angle was significantly higher in cups with polyethylene/steel articulation ($p = 0.027$). The other parameters showed no statistically significant differences between groups.

Pixel intensity (PI) analysis revealed that the highest mean values of periacetabular bone PI occurred in zone I and the lowest in zone III. This regularity

Table 2. Results of HHS evaluation form. Means from the groups examined

Harris Hip Score	HA-coated cups	Uncoated cups	<i>p</i> -value (the Mann–Whitney <i>U</i> test)
Pain	42.67	42.80	0.914
Function	40.50	43.50	0.664
Deformations	3.83	3.80	0.914
Range of motions	4.81	4.61	0.233
Total	91.81	94.71	0.828

Table 3. Results of HHS evaluation form. Means from the group with HA-coated cups with different articulations

Harris Hip Score	HA-coated cups		<i>p</i> value (the Mann-Whitney <i>U</i> test)
	Polyethylene/steel articulation	Ceramics/ceramics articulation	
Pain	42.00	43.00	0.633
Function	38.50	41.50	0.708
Deformations	3.50	4.00	0.178
Range of motions	4.80	4.82	0.953
Total	88.80	93.32	0.660

Table 4. Mean values from particular measurements just after surgery and two years after surgery.

The values in bold print represent statistically significant *p* values (change of measurements between primary X-ray and after 2 years)

Mean measuring values Parameter	Uncoated cups			HA-coated cups			
	After surgery (stan. dev.)	2 years after surgery (stan. dev.)	Change (stan. dev.) <i>p</i> value	After surgery (stan. dev.)	2 years after surgery (stan. dev.)	Change (stan. dev.) <i>p</i> value	
Tilt Inclination angle (I)	43.27 0 (4.68)	43.53 0 (4.58)	-0.27 0 (1.53) 0.512	46.35 0 (8.83)	47.53 0 (8.24)	-1.18 0 (1.29) 0.002	
Horizontal migration	Kohler line–cup tangent vertical line distance (SK)	5.09 mm (3.17)	4.14 mm (3.18)	0.95 mm (0.74) 0.0002	6.64 mm (3.70)	5.79 mm (4.19)	0.85 mm (0.87) 0.001
	Lower cup margin–Kohler tear distance (DK)	12.14 mm (4.20)	11.15 mm (4.05)	0.99 mm (0.90) 0.001	16.18 mm (5.60)	15.41 mm (6.06)	0.77 mm (0.80) 0.001
Vertical migration	Upper cup margin–both Kohler tears line distance (GKK)	49.26 mm (4.93)	50.29 mm (4.62)	-1.03 mm (1.57) 0.023	50.63 mm (8.56)	52.46 mm (9.56)	-1.83 mm (2.29) 0.005
	Lower cup margin–both Kohler tears line distance (DKK)	5.34 mm (7.01)	6.17 mm (7.17)	-0.83 mm (0.84) 0.002	4.36 mm (12.31)	4.75 mm (12.92)	-0.39 (1.03) 0.134

Table 5. Mean values of pixel intensities for each zone and *p* value (Student’s *t*-test for comparison of coated and uncoated cups)

Zone I (<i>p</i> = 0.46)	Zone II (<i>p</i> = 0.79)	Zone III (<i>p</i> = 0.79)	DeLee–Charnley zones
116.6	113.6	102.5	total
123.5	116.1	104.8	HA-coated
112.0	112.0	101.0	uncoated

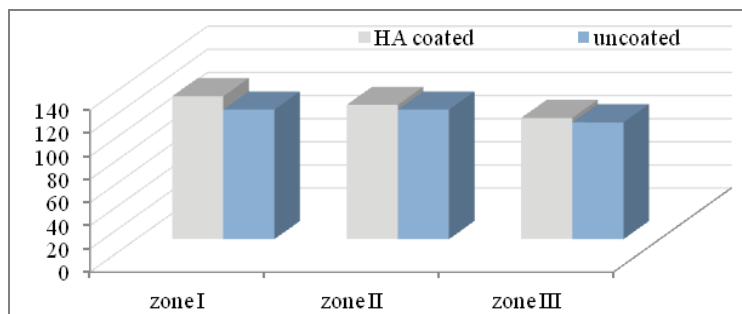


Fig. 3. Mean of pixel intensity (PI) values of bone tissue surrounding implant in the groups examined

concerned both groups (table 5). The values in the group with HA-coated cups were generally higher in

all three zones; however, these differences were not statistically significant (figure 3).

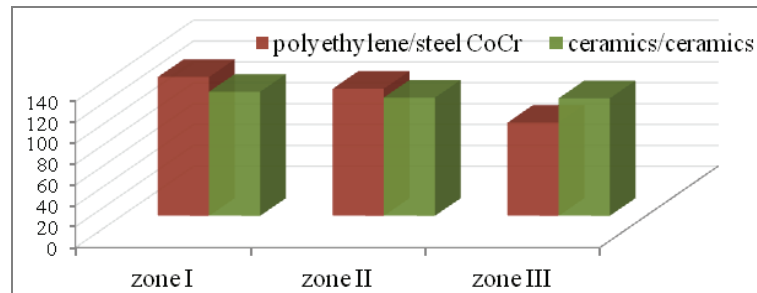


Fig. 4. Mean of pixel intensity (PI) values of bone tissue surrounding implant in the groups examined

Table 6. Mean values of pixel intensities for each zone and p value (Student's t -test for comparison of two various articulations)

Zone I ($p = 0.47$)	Zone II ($p = 0.68$)	Zone III ($p = 0.33$)	DeLee–Charnley zones
132.91	121.68	89.22	polyethylene/steel CoCr
118.84	113.27	112.64	ceramics/ceramics

Table 7. Type of cup fixation in bone according to Engh – number of cups in Engh groups

Cup fixation in bone (Engh)		HA-coated cups	Uncoated cups
1	Stable	7	6
2	Stable without bone ingrowth	7	9
3	Unstable	3	0

Table 8. Type of cup fixation in bone according to Engh – number of cups in Engh groups with two different articulations

Cup fixation in bone (Engh)		HA-coated cups	
		Polyethylene/steelCoCr	Ceramics/ceramics
1	Stable	1 (16.6%)	5 (50%)
2	Stable without bone ingrowth	4 (66.6%)	3 (30%)
3	Unstable	1 (16.6%)	2 (20%)

Within the group of patients with HA-coated cups PI measurements were conducted in order to compare articulations, but no statistically significant differences were noticed (figure 4, table 6).

The results of the implant–bone fixation assessment revealed that 15 uncoated and 14 HA-coated cups could be considered as stable (I and II types), 3 cups could be considered as unstable (III type), all three belonged to the HA-coated group. This gives 17.64% of results with poor prognosis in HA-coated group (9.37% in all hips). The differences between the groups examined were not statistically significant.

In the present study, the type of articulation did not affect the implant bone fixation ($p = 0.315$) (table 8). In the group with polyethylene/steel articulations, good and very good results were obtained for 83.2% of cups, whereas in the group with ceramics/ceramics articulations – for 80%.

4. Discussion

Previous clinical and experimental studies indicate that implant surface properties are essential for bone implant response and osseointegration providing a long-term functioning of the implant. However, these processes are still not fully understood. The use of biomimetic coatings like HA in orthopaedic surgery did not resolve important problems dealing with long-term bone implants as was mentioned in the introduction.

In the present study, the authors compared the results obtained for acetabular cups with varied bone contact surfaces. The observations were based on functional assessment but above all on X-ray analysis, roentgenometric measurements of cup migration, bone remodelling, bone implant fixation two years after implantation.

Except two patients with unstable cups (over 4-mm migration), usually the displacement value did not exceed 2 mm in both groups. An increase or a decrease of the measuring value was due to the directions of forces acting on the hip during load-bearing determining the direction of implant migration [9]. These directions were consistent with observations of other authors [12].

The evaluation of bone remodelling provides crucial information about osseointegration, but in an available literature the analysis of this process is usually based on densitometry [25], [26] or computed microtomography [27]. On the other hand, there is no indication for those routine tests because they expose patients to additional radiation. In this study, the authors evaluated routinely X-rays taken on postoperative checks in outpatient clinic, not disturbing standard postoperative proceedings. These X-rays were analysed and average pixel intensity values of bone at a distance of 5 mm from implant were measured in all the DeLee–Charnley zones. In our study, the distribution of PI varied, depending on zone. PI of periacetabular bone in zone I had the highest values (averaged 116.6), while the lowest occurred in zone III (102.5) (figure 3, table 5). These results correspond to bone density in DEXA analysis [23] and show that PI analysis on plain radiographs performed under standardized conditions is a reliable method of describing bone remodelling. The method does not need either any changes in post-operative routine, without exposing the patient to invasive tests, implantation of additional markers or radiation.

Three acetabular cups were assigned to the implants with high risk of early loosening. All three patients had THA with HA-coated cups. Only one cup of all poor outcomes was unstable in roentgenometric analysis and remaining two had unstable fixation, linear radiolucencies (osteolysis), and low values of PI. We analysed the factors leading to those results. Preoperative conditions, both local and general, and acetabular cup placement did not differ from those of other patients. Two patients had steel/polyethylene articulation, and one patient ceramics/ceramics articulation. The only feature which distinguished patients with poor outcome from the other was HA-coating. Therefore the authors made an assumption that a direct cause of cups failure might lie in the HA-coatings on their surface.

In an available literature, most authors in outcome evaluation of THA focused on implant survival – the period of proper functioning till implant loosening

with reoperation as the endpoint of the studies. In this study, we presented two-year observation – a relatively short period in comparison to an average time of proper function of endoprosthesis. However, adaptation occurring in first two years after surgery, such as cup migration, osteolysis, poor bone remodelling around the implant, determines the final outcome of surgical treatment [10], [14]. This means that in the first two-year period after THA it is possible to detect symptoms, predict final outcome but also to prevent some of the complications.

The data obtained in this study suggests that HA coatings on acetabular cup in THA do not improve their biological and mechanical properties and do not influence THA outcome. Stability, fixation, PI analysis, osteolysis incidence and bone remodelling surrounding implant did not prove superiority of HA-coated cups over titanium-uncoated cups. Any statistically significant differences between these two types of cup surface did not clearly answer the question as to which type had better clinical performance. Nevertheless the research performed suggests that HA coatings requiring additional biomaterial preparation do not protect against treatment failure. The incidence of loosening is not lower than in the case of other surfaces (such as titanium, tantalum); furthermore, it is often higher, especially when in THA with HA-coated cup a polyethylene articulation is used [28]–[30]. It is known that HA has osteoconductive potential, but because of a considerable fragility and low durability of HA coatings on metallic surfaces, such a layer is active only during first few months after implantation [7], [9]. HA coating does not accelerate tissue mineralization and does not stimulate significantly osteogenic cells [8]. As for the stem of THA some authors did not observe any differences in outcomes of HA-coated and uncoated titanium implants [31], [32], but there are some examples in literature indicating a clear therapeutic benefits and better clinical performance of HA-coated implants [33]. The studies on cementless acetabular cups reveal a clear predominance of reports with adverse effects on the survival of HA-coated cups or at least lack of differences between coated and uncoated cups [28]–[30]. Furthermore, HAVELIN et al. analyzed data from the Norwegian THA register and did not notice any significant differences in survival between cementless HA-coated cups and cemented cups [34]. BLACHA [35] and STILLING et al. [29] and others noticed that one of the major reasons for osteolysis and cup loosening is polyethylene wear [29], [35]. These observations made the authors to undertake a further THA outcome evaluation in patients with different articula-

tion types (ceramics/ceramics and polyethylene/steel); however, the results obtained did not confirm this observation. Comparison of all parameters (cup migration, bone remodelling (figure 4), fixation (table 8)) showed no statistically significant differences between THA with ceramics/ceramics or polyethylene/steel articulations.

In recent years, numerous reports on clinical outcomes of HA-coated implants and the present results ask questions about true reasons for clinical applications of such implants [28]–[30], [35]. HA effect on bone metabolism in first few months after surgery may be favourable [36]. However, in permanent biomaterials like implants for total joint arthroplasty, HA may be the cause of osteolysis and loosening-induced wear particles (“debris disease”). These concerns, long-term bone implant complications and their effects on host tissues cause that main goals of biomaterial engineering (implants more biocompatible, bio-functional) are still unattainable [1], [37]–[42].

5. Conclusions

Hydroxyapatite coatings on titanium cementless acetabular cups implanted in press-fit technique have no influence on their stability, bone–implant fixation and remodelling of bone surrounding implant two years after surgery. Percentage of cementless acetabular cups with poor fixation in bone and hence poor outcome prognosis with high risk of implant loosening concern particularly hydroxyapatite-coated cups.

Reference

- [1] HOZACK W., PARVIZI J., BENDER B. (ed.), *Surgical treatment of hip arthritis: reconstruction, replacement and revision*, 1st ed., Saunders, Elsevier, 2009.
- [2] HARRIS W.H., *Wear and periprosthetic osteolysis: the problem*, Clinical Orthopaedics and Related Research, 2001, 393, 66–70.
- [3] HERBERTS P., MALCHAU H., *Long-term registration has improved the quality of hip replacement: a review of the Swedish THR Register comparing 160,000 cases*, Acta Orthop. Scand., 2000, 71(2), 111–121.
- [4] ROBERTSSON O., KNUTSON K., LEWOLD S., LIDGREN L., *The Swedish Knee Arthroplasty Register 1975–1997: an update with special emphasis on 41,223 knees operated on in 1988–1997*, Acta Orthop. Scand., 2001, 72(5), 503–513.
- [5] MOOTANAH R., INGLE P., ALLEN E., CHEAH K., DOWELL J., JARRETT P., SHELTON J.C., *Total Hip Replacement: Improving the Cement Fixation of the Acetabular Component*, Proceedings of the 13th Conference of European Society of Biomechanics, Acta Bioeng. Biomech., 2002, 4, Supp. 1, 600–601.
- [6] BRANEMARK P.J., HANSSON B.O., ADELL R., BREINE U., LINDSTRÖM J., HALLAN O., ÖHMAN A., *Osseointegrated implants in the treatment of edentulous jaw*, Stockholm, Almqvist and Wksell, 1977.
- [7] SHEPPERD J.A.N., APHORP H., *A contemporary snapshot of the use of hydroxyapatite coating in orthopaedic surgery*, J. Bone Joint Surg., Aug 2005, 87, 8.
- [8] TONINO A.J., van der WAL B.C., HEYLIERS I.C., GRIMM B., *Bone remodeling and hydroxyapatite resorption in coated primary hip prostheses*, Clin. Orthop. Relat. Res., 2009, 467, 478–484.
- [9] CANALE S.T., BEATY J.H., *Campbell’s Operative Orthopaedics*, 11ed., Mosby, Elsevier, 2008.
- [10] CALLAGHAN J.J., DYSART S.H., SAVORY C.G., *The uncemented porous-coated anatomic total hip prosthesis. Two-year results of a prospective consecutive series*, J. Bone Joint Surg., (Am.) 1988, 70, 337–346.
- [11] DORR L.D., ZHINIAN W., *Ten Years Experience with Poured Acetabular Components for Revision Surgery*, Clinical Orthopaedics, 1995 October, Vol. 319.
- [12] ILCHMANN T., FREEMAN M.A.R., MJOBERG B., *Accuracy of the Nunn method in measuring acetabular cup migration*, Uppsala, J. Med. Sci., 97, 67–68.
- [13] SUTHERLAND C.J., WILDE A.H., BORDEN L.S., MARKS K.E., *A ten-year follow-up of one hundred consecutive Muller curved-stem total hip-replacement arthroplasties*, J. Bone Joint Surg., 1982, 64–A, 970–982.
- [14] WETHERELL R.G., AMIS A.A., HEATLEY F.W., *Measurement of acetabular erosion*, J. Bone Joint Surg., 1989, 71-B, 447–451.
- [15] ENGH C.A., BOBYN J.D., GLASSMAN A.H., *Porous-coated hip replacement. The factors governing bone ingrowth, stress shielding, and clinical results*, J. Bone and Joint Surg., 1987, 69-B(1), 45–55.
- [16] MASSIN P., SCHMIDT L., ENGH C.A., *Evaluation of cementless acetabular component migration. An experimental study*, J. Arthroplasty, 1989, 4, 245.
- [17] www.depuy.com (dostęp: 27 lipca 2011).
- [18] <http://www.bbraun.com> (dostęp: 27 lipca 2011).
- [19] <http://www.stryker.com> (dostęp: 07 sierpień 2011).
- [20] <http://www.biomet.com> (dostęp: 08 sierpień 2011).
- [21] SÖDERMAN P., MALCHAU H., *Is the Harris hip score system useful to study the outcome of total hip replacement?* Clin. Orthop. Relat. Res., 2001 Mar., 384, 189–197.
- [22] MAHOMED N.N., ARNDT D.C., McGRORY B.J., HARRIS W.H., *The Harris hip score: Comparison of patient self-report with surgeon assessment*, The Journal of Arthroplasty, August 2001, 16(5), 575–580.
- [23] DeLEE J.G., CHARNLEY J., *Radiological demarcation of cemented sockets in total hip replacement*, Clin. Orthop. Relat. Res., 1976 Nov–Dec, 121, 20–32.
- [24] MANLEY M.T., CAPELLO W.N., D’ANTONIO J.A., EDIDIN A.A., GEESINK R.G., *Fixation of acetabular cups without cement in total hip arthroplasty. A comparison of three different implant surfaces at a minimum duration of follow-up of five years*, J. Bone Joint Surg. Am., 1998, 80(8), 1175–1185.
- [25] BLOEBAUM R.D., LIAU D.W., LESTER K.D., ROSENBAUM T.G., *Dual-energy X-ray absorptiometry measurement and accuracy of bone mineral after unilateral total hip arthroplasty*, The Journal of Arthroplasty, 2006, 21(4).
- [26] AKHAVAN S., MATTHIESEN M.M., SCHULTE L., PENOYAR T., KRAAY M.J., RIMNAC C.M., *Clinical and histologic results*

- related to a low-modulus composite total hip replacement stem, *J. Bone Joint Surg.*, June 2006, 88-A(6).
- [27] MENEGHINI R.M., FORD K.S., MCCOLLOUGH C.H., HANSSON A.D., LEWALLEN D.G., *Bone remodeling around porous metal cementless acetabular components*, *The Journal of Arthroplasty*, 2010, 25(5), 741–747.
- [28] GARELLICK G., KÄRRHOLM J., ROGMARK C., HERBERTS P., *Swedish Hip Arthroplasty Register Annual Report, 2008*.
- [29] STILLING M., RAHBK O., SÖBALLE K., *Inferior survival of hydroxyapatite versus titanium-coated cups at 15 years*, *Clin. Orthop. Relat. Res.*, 2009, 467, 2872–2879.
- [30] LAZARINIS S., KÄRRHOLM J., HAILER N.P., *Increased risk of revision of acetabular cups coated with hydroxyapatite. A Swedish Hip Arthroplasty Register study involving 8,043 total hip replacements*, *Acta Orthopaedica*, 2010, 81(1), 53–59.
- [31] CAMAZZOLA D., HAMMOND T., GANDHI R., DAVEY J.R., *A randomized trial of hydroxyapatite-coated femoral stems in total hip arthroplasty. A 13-year follow-up*, *The Journal of Arthroplasty*, 2009, 24(1).
- [32] LEE J.M., LEE C.W., *Comparison of hydroxyapatite-coated and non-hydroxyapatite-coated noncemented total hip arthroplasty in same patients*, *The Journal of Arthroplasty*, 2007, 22(7).
- [33] VIDALAIN J.P., *Corail stem long-term results based upon the 15-year artro group experience*, [in:] Epinette J.A., Manley M.T. (ed.), *Fifteen years of clinical experience with hydroxyapatite coatings in joint arthroplasty*, Springer, France, 2004, p. 217.
- [34] HAVELIN L.I., ESPEHAUG B., ENGESAETER L.B., *The performance of two hydroxyapatite-coated acetabular cups compared with Charnley cups from the Norwegian Arthroplasty Register*, *J. Bone Joint Surg. [Br]*, 2002, 84-B, 839–845.
- [35] BLACHA J., *High osteolysis and revision rate with the hydroxyapatite-coated ABG hip prostheses: 65 hips in 56 young patients followed for 5–9 years*, *Acta Orthop. Scand.*, 2004, 75, 276–282.
- [36] MORONI A., FALDINI C., PEGREFFI F., HOANG-KIM A., GIANNINI S., *Hydroxyapatite coating of fixation devices for osteoporotic bone*, *J. Bone Joint Surg. [Br]*, 2005, 87-B, suppl I, 55.
- [37] PARK J., LAKES R.S., *Biomaterials. An Introduction*, third edition, Springer, 2007.
- [38] PULEO D.A., BIZIOS R., *Biological Interactions on Materials Surfaces Understanding and Controlling Protein, Cell and Tissue Responses*, Springer, LLC 2009.
- [39] JUNKER R., DIMAKIS A., THONEICK M., JANSEN J.A., *Effects of implant surface coatings and composition on bone integration: a systematic review*, *Clin. Oral. Impl. Res.*, 2009, 20 (Suppl. 4), 185–206.
- [40] BERRY D.J., STEINMANN S.P. (ed.), *Adult Reconstruction*, 1st ed., Williams & Wilkins, 2007.
- [41] MASON J.B., *The new demands by patients in the modern era of total joint arthroplasty. A point of view*, *Clin. Orthop. Relat. Res.*, 2008, 466, 146–152.
- [42] WODZISLAWSKI W., KRUPA S., NOWICKI J., BĘDZIŃSKI R., DETYNA J., *The reaction of the pelvis to the implantation of the acetabular component of the hip endoprosthesis – initial tests with the use of computerized tomography*, *Acta Bioeng. Biomech.*, 2009, 11(4), 45–54.
- [43] CHERNIAKOVA YU.M., PINCHUK L.S., *Tribological aspects of joint intraarticular therapy*, *Acta Bioeng. Biomech.*, 2011, 13(1), 57–63.