

The change of volume of the lumbar vertebrae along with aging in asymptomatic population: a preliminary analysis

GRZEGORZ MIĘKISIAK^{1*}, DARIUSZ ŁĄTKA¹, WITOLD JANUSZ², WIKTOR URBAŃSKI³,
RAFAŁ ZAŁUSKI⁴, ŁUKASZ KUBASZEWSKI⁵

¹ Department of Neurosurgery, University Hospital, Opole, Poland.

² Department of Neurosurgery and Pediatric Neurosurgery, Medical University of Lublin, Poland.

³ Department of Orthopedics and Traumatology, Wrocław Medical University, Wrocław, Poland.

⁴ Department of Neurosurgery, Wrocław Medical University, Wrocław, Poland.

⁵ Department of Orthopedics and Traumatology, W. Dega University Hospital, Poznań, Poland.

Introduction: Previous studies have demonstrated that the length of the lumbar spine is decreasing with age. Despite considerable research based on sagittal measurements, little is known about the changes in the volume of vertebrae. The objective of this study was to evaluate the changes in the volume of either column of the spine with age. *Materials and methods:* Computed tomography scans of 62 asymptomatic subjects, performed for thoracolumbar trauma evaluation were used to create virtual 3D models. At least 10 patients were assigned to every decade of life from third to eight. We used a novel technique to measure the volume of anterior column (AC) and posterior column (PC) per each segment (a total of 310 segments). Midline sagittal images were used to measure disc height (DH) and vertebral body height (VH). *Results:* With age, both DH increases, whereas the VH decreases. The overall length of lumbar segment of the spine decreases with age. The volumetric measurements performed on same subjects showed that volume of both AC and PC does not change with age in females. In males, there is a weak but statistically significant correlation between AC volume and age and no change in the volume of PC. The ratio of PC:AC volume does not change with age in women, although it decreases slightly but significantly (in favor of AC) with age in males. *Conclusions:* The overall length of lumbar spine decreases with age. This process is not a result of mere changes in the volume of either AC or PC.

Key words: lumbar spine alignment, Voxel-based morphometry, aging, asymptomatic population

1. Introduction

The human spine is a complex, modular, load-bearing structure that provides protection to neural structures within a considerable range of movement. With age, two parallel but independent processes occur in the elements of anterior column, namely, reduction of bone mineral density (BMD) and the development of degenerative changes [1]. These processes affect the global alignment of the spine, depending greatly on the degree of disc degeneration [2].

Significant research has been devoted to the role of interbody discs in aging. However, much less attention has been paid to age-related changes in the structure of vertebral bodies. It has been shown that the overall length of lumbar spine decreases [3], [4] with age, but the exact mechanism remains elusive. Moreover, there are a few literature works on the effects of aging on interbody discs, but the data is conflicting [4], [5]. The evidence on similar changes occurring in the vertebrae with aging is very scarce and majority of studies are based on either magnetic resonance imaging (MRI) or CT. This approach, compared with cadaveric studies, allows for more precise and unbiased results, as post-

* Corresponding author: Grzegorz Miękiśiak, Department of Neurosurgery, University Hospital, al. Witosa 26, 46-020 Opole, Poland. Phone: +48 77 45 20 722, e-mail: gmiekiśiak@gmail.com

Received: June 24th, 2018

Accepted for publication: July 8th, 2018

mortem changes affect the overall volume of the spine [6]. In addition, the use of modern imaging techniques enables the three-dimensional quantitative evaluation of the volume [7].

The present study is a CT-based, morphometric study where a crosssectional evaluation of the volume of anterior and posterior columns of the spine in different age groups were performed. A novel technique was introduced that allowed for precise, semi-automated measurements based on CT scans. The current study assessed the impact of aging on the volume of both anterior and posterior columns of the lumbar spine. To our knowledge, this is one of the first studies to analyze the changes in volume of both columns of the spine occurring with aging.

2. Materials and methods

The data was retrospectively collected from hospital records. All patients were 20 years of age or older. They had presented to the Emergency Department for thoracolumbar trauma evaluation over a period of 2 years. The exclusion criteria included: (1) presence of spinal fracture(s), (2) total collapse of any disc space (3), severe osteophyte formation, (4) lumbalization/sacralization in the lumbosacral junction, and (5) spondylolysis. Subjects were divided into six crosssectional age groups by decades, from 3rd to 8th. All CTs were acquired with a single 64-slice helical CT scanner (Somatom Sensation 16; Siemens Medical Solutions; Germany) with the B80f reconstruction kernel (bone-window). The accepted slice thickness was 1 to 1.5 mm. Volumetric measurements were performed with the 3DimViewer program (3Dim Laboratory s.r.o., Czech Republic), a medical-grade software designed to process volumetric CT data for fabricating molding forms for custom-made implants, especially for reconstruction of cranial defects. The segmentation was performed in a semi-automatic fashion based on the signal intensity. First, the axial images were stacked up, thereby creating a 3D model. An automated thresholding was performed, removing all pixels with the intensity lower than 180 to 200 Hounsfield Units (HU). Then, in a semi-automated fashion, the segment of interest was extracted. Remaining elements were expanded by 2 pixels in all directions. Any voids within the vertebrae were filled using a combination of an automated tool and manual editing. The models were then shrunk back down by 2 pixels. The final model (Fig. 1) was divided into anterior column (AC) and posterior column (PC) by

cutting it in coronal plane across the middle of pedicles. Volume was recorded per lumbar level. To account for individual variability in size of subject, the ratio of PC volume to AC volume was calculated. The height of the disc (DH) and vertebral body height (VBH) were calculated at all levels from L1 to S1 in the midsagittal plane, using the same software. The overall L1–S1 length (TL) is a total sum of all lengths.

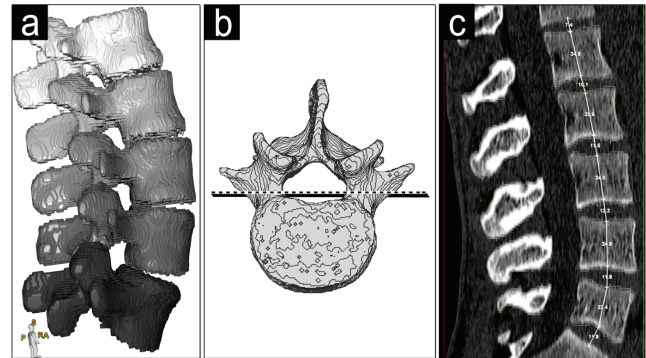


Fig. 1. Exemplary 3D model for volumetric measurement (a), the cutting plane dividing vertebrae into AC and PC (b), mid-sagittal measurements (c)

An independent investigator rechecked the consistency and accuracy of our method by assessing the inter-observer agreement of measurement by performing segmentation and volume measurement in 10 randomly selected patients (one per each decade of life).

Normality of volume and height distribution was assessed with the Kolmogorov–Smirnov (K–S) test. The relationship between volumes of each part and age as well as HD, VBH, and TL was evaluated with Pearson’s correlation test. The following thresholds for Pearson’s correlation coefficients (PCC) were accepted: ≤ 0.19 as very weak, 0.20–0.39 as weak, 0.40–0.59 as moderate, 0.60–0.79 as strong, and ≥ 0.80 as very strong [8]. The differences in mean values between genders were evaluated with the *t*-test. For the purpose of this study, we assumed the significance level of 0.05.

The study was approved by the local ethics committee.

3. Results

The present study included data from 62 subjects out of a total of 76 screened. There were 31 males aged 20 to 73 years and 31 females aged 20 to 78 years. The mean age for males and females was 49.45 (SD 17.28)

and 49.61 (SD 17.49) years, respectively. There were 10 patients (5 males and 5 females) per each decade of life except for 6 males in their seventh decade and six females in their sixth decade.

Sagittal Measurements

Sagittal measurements are depicted in Fig. 2. The VBH, TL, and DH were normally distributed according to the K–S test. There was a weak but statistically significant negative correlation between TL and age ($r = -0.35; p < 0.01$). A moderate negative correlation was found between VBH and age ($r = -0.53; p < 0.0001$), whereas the positive correlation between DH and age was weak ($r = 0.26; p < 0.0001$).

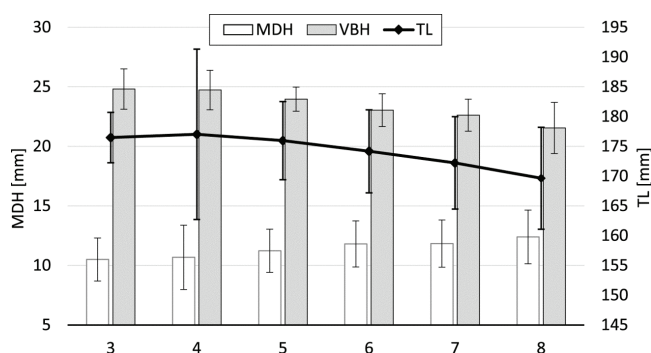


Fig. 2. Sagittal measurements. As the vertebral body height (VBH) decreases the disc height (DH) increases, the overall length (TL) is also increasing

Volume measurements

The results of volumetric measurements are shown in Figures 3 and 4. The mean volume of male and female ACs was 46.96 (SD 4.86) cm³ and 36.73 (SD 5.85) cm³, respectively. The difference was statistically significant at $p < 0.0001$. In all age groups but one, the volume of AC increased gradually from L1 to L4 with the volume at L5. The largest mean volume of AC for females was in the fourth decade of life, whereas for males it was recorded in their seventh decade. There was weak but statistically significant correlation of AC volume and age in males: PCC = 0.21 ($p = 0.008$) (Fig. 3 top). No such correlation was observed for females. The mean volume of male PCs was 23.46 (SD 4.13) cm³, whereas same measurement for females was 19.07 (SD 3.33) cm³ ($p < 0.0001$). The volume of PC decreased slightly with age in both genders; however, the correlation was not statistically significant (Fig. 4). It was the lowest at the L1 and L2 in all age groups. The mean ratio of PC:AC (Fig. 5) volume was 0.50 (SD 0.07) for males and 0.52 (SD 0.08) for females, the difference was not statistically significant.

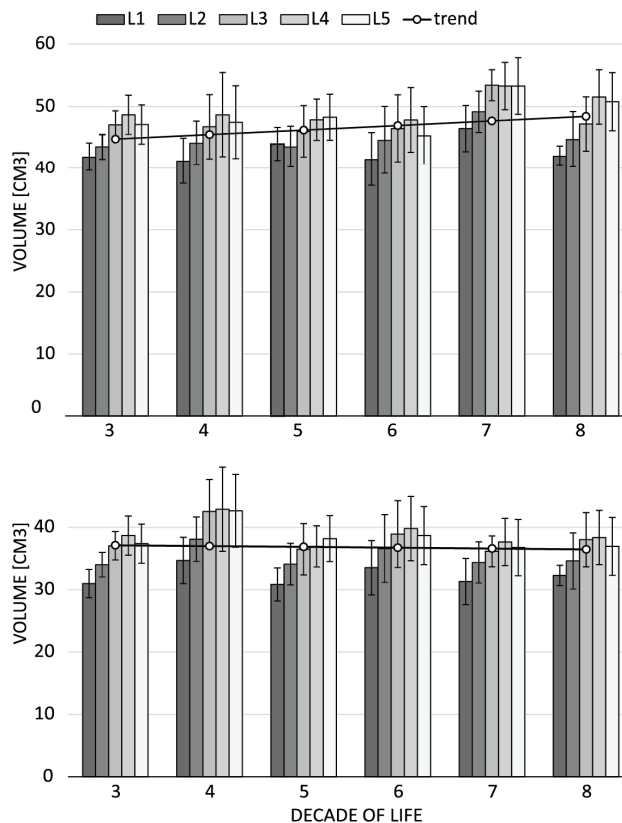


Fig. 3. The mean volume of AC per decade of life. Top figure males, bottom figure females

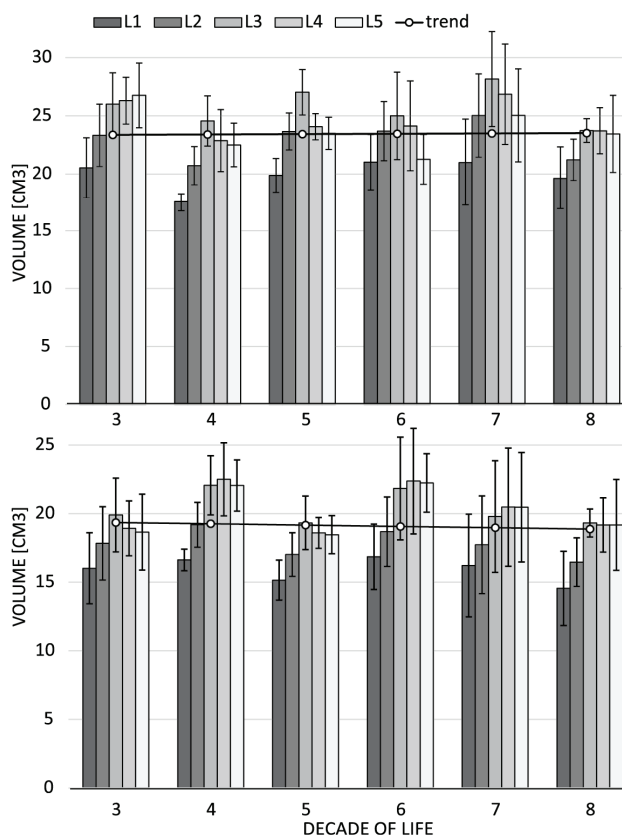


Fig. 4. The mean volume of PC per decade of life. Top figure males, bottom figure females

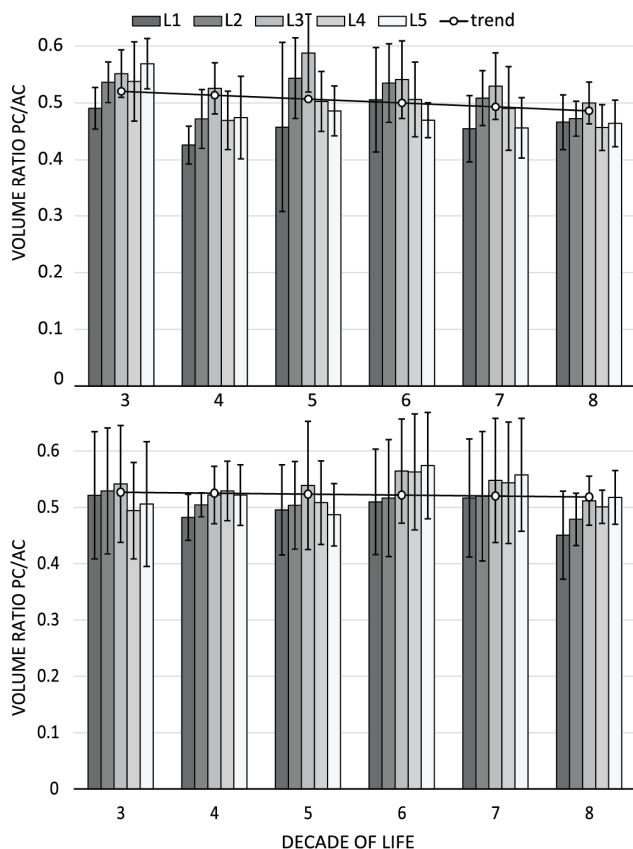


Fig. 5. The PC:AC volume ratio per decade of life.
Top figure males, bottom figure females

4. Discussion

The present study, to the best of our knowledge, is the first study that evaluates the changes in volume of AC and PC of the spine occurring with age. It was accomplished with the use of novel software designed for segmentation and volumetric measurement based on CT scans. Various techniques have been used in the past to assess the volume of VBs. The most simple approach treats vertebral bodies as cylinders, and the volume is calculated with a respective formula [9]. Other methods utilized the Cavalieri principle, in which the volume of irregularly shaped objects could be estimated from a set of two-dimensional slices through the object, provided that they are parallel, separated by a known distance, and begin randomly within the object. These criteria are met by standard CT [10]. Although this technique has been proven valid for the measurement of vertebral bodies [10] for smaller parts, such as the elements comprising the PC, this method would be tedious and likely inaccurate. Another difficulty in the evaluation of spinal volume comes from the presence of bony irregularities, such

as osteophytes, which make simplistic models of vertebral bodies grossly inaccurate [7]. Limthongkul et al. [11] used the dedicated computer software with manually outlined vertebral bodies. The biggest drawback of this method is its reliance on human input and significant workload, as each level has to be manually outlined on a series of scans. Therefore, it would be particularly difficult to apply in the measurement of PE.

The most straightforward solution for automated measurement would be to utilize the thresholding of CT scans. However, as the bone is highly heterogeneous, this technique would result in a highly porous model, with many voids. In our method, the thresholding is merely an initial step, and the main innovation is the employment of advanced algorithm to close 3D gaps, thereby creating an accurate stack of voxels. The most labor-intensive step of the process is segmentation of spine into levels, especially with narrow-facet joint gaps. This is potentially the greatest source of error. The consistency of this method was evaluated by repeated measurements by independent observers, and it has been shown that the values were very consistent for both AC and PC volumes. The present study demonstrated that the mid-sagittal DH increased with age. Similar to our findings, several studies found a positive correlation between age and disc height. Shao et al. [12] noticed that lumbar disc height linearly increased with age. Twomey and Taylor [5], [13] reported that the DH increased with age as the discs sunk into vertebrae, thus decreasing the height of VB. This observation is consistent with our work, as we were able to show that the VB height decreased significantly over lifetime. Similar results were reported by Sevinc et al. [14] and Diacinti et al. [3]. It was also found by other authors that the process of embedding of intervertebral discs into adjacent VBs correlated with the loss of BMD [7], [15]. The resulting overall shortening of AC had an impact on the loss of stature in the elderly [15]. Although it is possible that this process affects the global spinal alignment, some authors argue that the predominant cause is decreasing disc height [16].

The current study concluded that the changes in sagittal parameters described above were not reflected in the changes of volume. There was only a modest age-related increase in the AC volume in males without significant changes in females. The former is likely to be caused by the accumulation of osteophytes or other forms of bone overgrowth. Therefore, the loss of height in sagittal plane cannot be explained merely by the loss of volume of PC. It is more likely the result of flattening of the vertebrae. It cannot be ruled out that that the overall loss of volume is somewhat compen-

sated by peripheral overgrowth of bone i.e., generation of osteophytes. The relative overgrowth of the AC was found to be a major culprit of development of adolescent idiopathic scoliosis [17]. However, to our knowledge, the changes of relationship between the volume of both columns of the spine occurring with age has not been studied.

Despite the information of lumbar facet arthrosis occurring with age [18], [19] being well-known and available in the literature we were unable to demonstrate significant changes in the volume of PC. Lv et al. [20] found a correlation between the degree of degeneration of facet joints and the impairment of sagittal balance expressed as increased pelvic tilt. However, a causal relationship was not established. In our work, the volume ratio AC/PC was found to decrease slightly with age, in favor of AC relative overgrowth. How this process affects changes in the global sagittal profile of the lumbar spine occurring with aging is yet to be studied.

The present study has certain limitations. The lack of correlation between volume and age in females could be the result of individual variability of the size of individuals as this was a non-longitudinal study design. To account for that, we decided to evaluate the AC/PC volume ratio. The sample size was rather small, but sufficient enough to demonstrate significant changes in sagittal measurements. These changes cannot be supported merely by the loss of volume. The semi-automatic segmentation of CT-based images can potentially be a source of error. Therefore, we performed the test–retest analysis that showed good consistency of measurements. Last but not least, we realize this study would benefit greatly with the inclusion of data on the BMD, as it has been already shown that the bone volume depends greatly on bone quality [21].

The present study is the first preliminary analysis of the impact of aging on volume of the lumbar spine, and further work is required to completely understand this process.

In conclusion, a gradual shortening of the AC was noted in the asymptomatic population, by sinking of discs into vertebral bodies. These changes did not correlate with the decrease in AC volume. In fact, in the male population, the AC volume increased with age, and the PC volume did not change significantly with age.

Acknowledgments

The authors would like to thank the 3Dim Laboratory for providing the software for analysis.

The authors declare no conflict of interest.

References

- [1] PAPADAKIS M., SAPKAS G., PAPADOPOULOS E.C., KATONIS P., *Pathophysiology and biomechanics of the aging spine*, Open Orthop. J., 2011, 5, 335–542.
- [2] KIM Y.B., KIM Y.J., AHN Y.-J., KANG G.-B., YANG J.-H., LIM H., LEE S.-W., *A comparative analysis of sagittal spinopelvic alignment between young and old men without localized disc degeneration*, Eur. Spine J., 2014, 23, 1400–1406.
- [3] DIACINTI D., ACCA M., D'ERASMO E., TOMEI E., MAZZUOLI G.F., *Aging changes in vertebral morphometry*, Calcif. Tissue Int., 1995, 57, 426–429.
- [4] VIDEMAN T., BATTIÉ M.C., GIBBONS L.E., GILL K., *Aging changes in lumbar discs and vertebrae and their interaction: a 15-year follow-up study*, Spine J., 2014, 14, 469–478.
- [5] TWOMEY L.T., TAYLOR J.R., *Age changes in lumbar vertebrae and intervertebral discs*, Clin. Orthop. Relat. Res., 1987, 97–104.
- [6] JOHNSTONE B., URBAN J.P., ROBERTS S., MENAGE J., *The Fluid Content of the Human Intervertebral Disc. Comparison Between Fluid Content and Swelling Pressure Profiles of Discs Removed at Surgery and Those Taken Postmortem*, Spine, (Phila. Pa. 1976), 1992, 17, 412–416.
- [7] KWOK A.W.L., WANG Y.-X.J., GRIFFITH J.F., DENG M., LEUNG J.C.S., AHUJA A.T., LEUNG P.C., *Morphological Changes of Lumbar Vertebral Bodies and Intervertebral Discs Associated With Decrease in Bone Mineral Density of the Spine*, Spine, (Phila. Pa. 1976), 2012, 37, E1415–E1421.
- [8] EVANS J.D., *Straightforward statistics for the behavioral sciences*, Pacific Grove Calif.: Brooks/Cole Pub. Co., 1996.
- [9] CAULA A., METMER G., HAVET E., *Anthropometric approach to lumbar vertebral body volumes*, Surg. Radiol. Anat., 2016, 38, 303–308.
- [10] ODACI E., SAHIN B., SONMEZ O.F., KAPLAN S., BAS O., BILGIC S., BEK Y., ERGÜR H., *Rapid estimation of the vertebral body volume: a combination of the Cavalieri principle and computed tomography images*, Eur. J. Radiol., 2003, 48, 316–326.
- [11] LIMTHONGKUL W., KARAIKOVIC E.E., SAVAGE J.W., MARKOVIC A., *Volumetric analysis of thoracic and lumbar vertebral bodies*, Spine J., 2010, 10, 153–158.
- [12] SHAO Z., ROMPE G., SCHILTENWOLF M., *Radiographic changes in the lumbar intervertebral discs and lumbar vertebrae with age*, Spine, (Phila. Pa. 1976), 2002, 27, 263–268.
- [13] TWOMEY L., TAYLOR J., *Age changes in lumbar intervertebral discs*, Acta Orthop. Scand., 1985, 56, 496–499.
- [14] SEVINC O., BARUT C., IS M., ERYORUK N., SAFAK A.A., *Influence of age and sex on lumbar vertebral morphometry determined using sagittal magnetic resonance imaging*, Ann. Anat. – Anat. Anzeiger, 2008, 190, 277–83.
- [15] BARON Y.M., BRINCAT M.P., CALLEJA-AGIUS J., CALLEJA N., *Intervertebral disc height correlates with vertebral body T-scores in premenopausal and postmenopausal women*, Menopause Int., 2009, 15, 58–62.
- [16] VERNON-ROBERTS B., PIRIE C.J., *Degenerative changes in the intervertebral discs of the lumbar spine and their sequelae*, Rheumatol. Rehabil., 1977, 16, 13–21.
- [17] GUO X., CHAU W.W., CHAN Y.L., CHENG J.C.Y., *Relative anterior spinal overgrowth in adolescent idiopathic scoliosis. Results of disproportionate endochondral-membranous bone growth*, J. Bone Joint Surg. Br., 2003, 85, 1026–1031.

- [18] EUBANKS J.D., LEE M.J., CASSINELLI E., AHN N.U., *Prevalence of lumbar facet arthrosis and its relationship to age, sex, and race: an anatomic study of cadaveric specimens*, Spine, (Phila. Pa. 1976), 2007, 32, 2058–2062.
- [19] MASTER D.L., EUBANKS J.D., AHN N.U., *Prevalence of concurrent lumbar and cervical arthrosis: an anatomic study of cadaveric specimens*, Spine, (Phila. Pa. 1976), 2009, 34, E272-E275.
- [20] LV X., LIU Y., ZHOU S., WANG Q., GU H., FU X., DING Y., ZHANG B., DAI M., *Correlations between the feature of sagittal spinopelvic alignment and facet joint degeneration: a retrospective study*, BMC Musculoskelet. Disord., 2016, 17, 341.
- [21] YANG Z., GRIFFITH J.F., LEUNG P.C., LEE R., *Effect of Osteoporosis on Morphology and Mobility of the Lumbar Spine*, Spine, (Phila. Pa. 1976), 2009, 34, E115–E121.