

Treatment ways after the fracture of upper part of femur in the aspect of early patient's function

GRZEGORZ KONIECZNY, ZDZISŁAWA WRZOSEK

Department of Physiotherapy, University School of Physical Education,
ul. Rzeźbiarska 4, 51-629 Wrocław, Poland

Proximal femoral fractures occur most often in people over 60 (mainly women), that is, people whose physical fitness is already somehow limited. That is why proper choice of therapeutic management (conservative therapy or surgical procedure) is so crucial. As conservative therapy is connected with long-term hypokinesia, management of surgical procedure seems to be justified – it mobilises the patient early. We analysed 24 cases of patients with fracture of proximal part of femur treated in 4 four different ways. The first two groups comprised patients with fracture of the neck of the femur. Some of them were treated by implantation of endoprosthesis (group I), others by functional therapy (group II). The next two groups comprised patients with trochanteric fracture. Some of these patients were treated using DHS system (group III) and others with the aid of tractor (group IV). Analysis of the above groups concerns movement and functional possibilities of the patients from the beginning of rehabilitation process to the second week of its realisation.

Key words: fracture, proximal part of femur, movement and functional restraints, rehabilitation

1. Introduction

Fracture impairs the functioning of the movement system, which is particularly true when trauma concerns locomotion limbs. It follows from the medical statistics that more and more fractures of the proximal part of the femur occur as people get older and the large number of fractures in elderly patients is the negative effect of osteoporosis [2], [3], [5]. Within fracture prophylaxis the most adequate proper procedure is to prevent osteoporosis, which is nowadays possible owing to advanced medical knowledge. When, however, bone fracture occurs it is very important to treat the patient in a way which enables him/her to regain physical fitness to the highest degree possible.

Proximal femoral fractures most often occur in people over 60 (mainly women), that is, people whose physical fitness is already somehow limited. That is why proper choice of therapeutic management (conservative therapy or surgical procedure) is so crucial. As

conservative therapy is connected with long-term hypokinesia, management of surgical procedure seems to be justified – it mobilises the patient early [6], [7], [10].

Fractures of proximal part of the femur can be divided into: intracapsular fracture of the femoral neck and trochanteric fractures, which can be divided into pretrochanteric, intertrochanteric and subtrochanteric ones. We classify fractures of the neck of femur according to Pauwels and Garden and the trochanteric fractures according to Boyd and Griffin with Kyle's and Gusto's modifications, which take into consideration the indications and contraindications for various methods of surgical procedure [1].

All fractures heal according to pathophysiology union of fractured bone right, but healing of the femoral neck fracture is particularly unprofitable because of specific anatomical and pathomechanical conditions. Among them are proximal fragment ischemia and great instability of fracture [7]. Investigations showed that necessary conservative therapy of the femoral neck, that is, age-dependent and connected with age loading of this therapy, is most effective when applying functional therapy. The latter relies on the assemblage of above-ankle skeletal traction and limb position on Cruca's or Müller's functional splint with adequate loading. Such a treatment lasts 6–10 weeks and restrains patient's functional abilities.

Specific conditions accompanying femoral neck fracture mentioned above, typical of the femoral head vascularization and lack of periosteum in under-headed part, can cause complications, such as aseptic necrosis of the femoral head and false joint. Therefore, in the case of patient's qualification to surgical procedure, most often, femoral prosthesis is implanted with the use of cement, which allows early tilting patient to erect position [4], [8], [10].

Trochanteric fracture is an injury of the upper part of the femur localised between extracapsular part of femoral neck and about 3 cm below small trochanter. This part of femur is surrounded by numerous muscles and is well supplied with blood, which creates advantageous conditions for the union of fractured bone. In the case of trochanteric fractures, the degree of instability is very important, because the choice of treatment method depends on it. Most of the trochanteric fractures lack anatomical conditions for endoprosthesis implantation. Endoprosthesis implantation might allow early loading of lower limb, similar as in femoral neck fracture. In stable fractures the possibility of early loading depends on operative back-medial reconstruction of trochanteric area. This extensive reconstruction is connected with high level of risk or impossibility of making operation in the group of elderly patients.

Surgical procedure allows early mobilisation of patients, which really reduces the risk of long-term immobilisation consequences. In the case of patients with high risk of life threat during operation, the risk level is the same as during conservative therapy: traction therapy, functional therapy. Improving the conditions of nursing care and rehabilitation in conservative therapy stimulates progress in fracture healing. This process is counted in weeks from injury.

An example of connection of pretrochanteric and intertrochanteric fractures is DHS (Dynamic Hip Screw). It relies on adaptation of massive screw in the femoral neck and stable, compressed connection between screw and metal plate fixed to femoral body. Stability loss in osteolysis period may occur.

In patients with trochanteric fracture not being qualified for operation also conservative therapy is applied [9]. Usually skeletal tractor for femoral epicondyles is used, seldom for tuberosity of tibia or distal metaphysis of shin. Patients during hospitalisation are placed in bed with 30° flexion of hip and knee joints and also 30° abduction of hip joint in intermediate rotation. Skeletal traction even with large displacement of fragments is efficient. Loading rarely exceeds 6–8 kg giving fracture reposition in a few days. After 5–7 days and then 2 weeks periodic X-ray examination is made. Within this period of time, if necessary, some correction can be introduced: fragments reposition, tractor loading and limb positioning. After possible correction tractor should be used for 8–10 weeks together with mobilisation therapy.

2. The subject matter and objective of the study

The subject of the study was patients' movement abilities after the fracture of the proximal part of the femur during early mobilisation period, particularly movement and functional restraints connected with ways of treatment. The following objectives of the study were defined:

- comparison of the various methods of therapy after the fracture of the proximal part of femur in the range of active movement possibilities of limb in hip joint in the sagittal plane – flexion,
- comparison of the efficacy of different treatment ways in terms of physical fitness recovery in the area of bed and locomotion,
- comparison of the effects of various ways of treatment after the fracture of the proximal part of femur in the range of self-dependence.

3. Material and methods

The factors qualifying patients for the study were the same sex and comparative age 65–70. The group under study consisted of 24 women, who were treated at Orthopaedic Department of Wroclaw Medical University in 1997–2001. They sustained fracture of the upper part of femur. Since the treatment procedure depends on localisation and morphology of fracture the following methods were taken into consideration in the study. Finally, they were set 4 equal groups of patients: surgical procedure – implantation of Austin-Moore's endoprosthesis (group I) (figure 1) or

DHS system – Dynamic Hip Screw (group III) (figure 2) and conservative therapy – functional therapy (group II) (figure 3) or traction therapy (group IV).

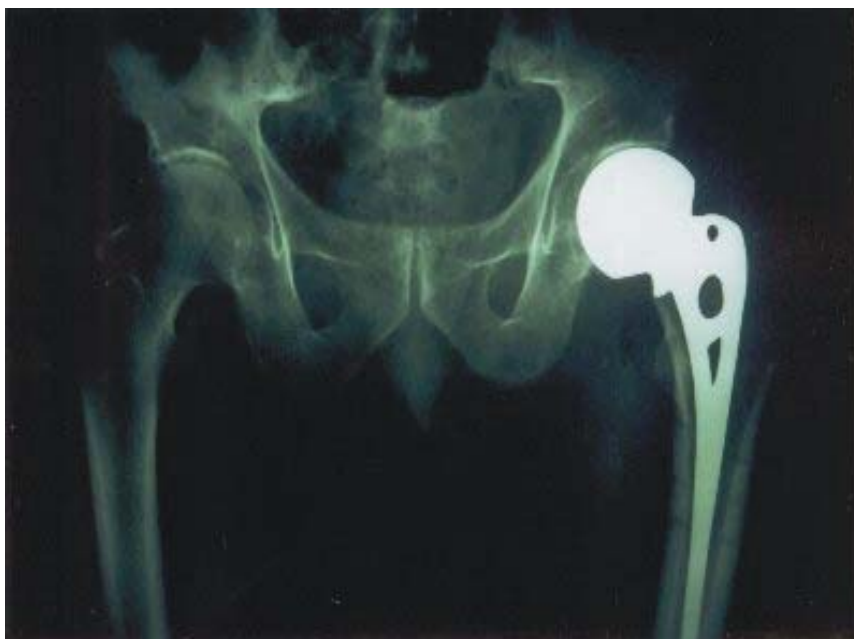

Fig. 1. Austin–More’s endoprosthesis after implantation

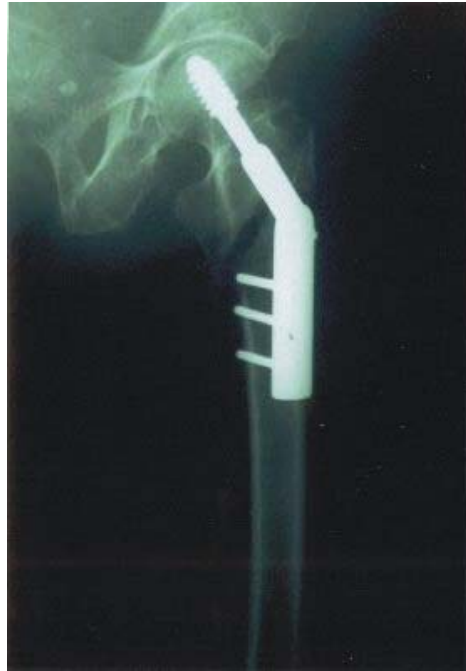
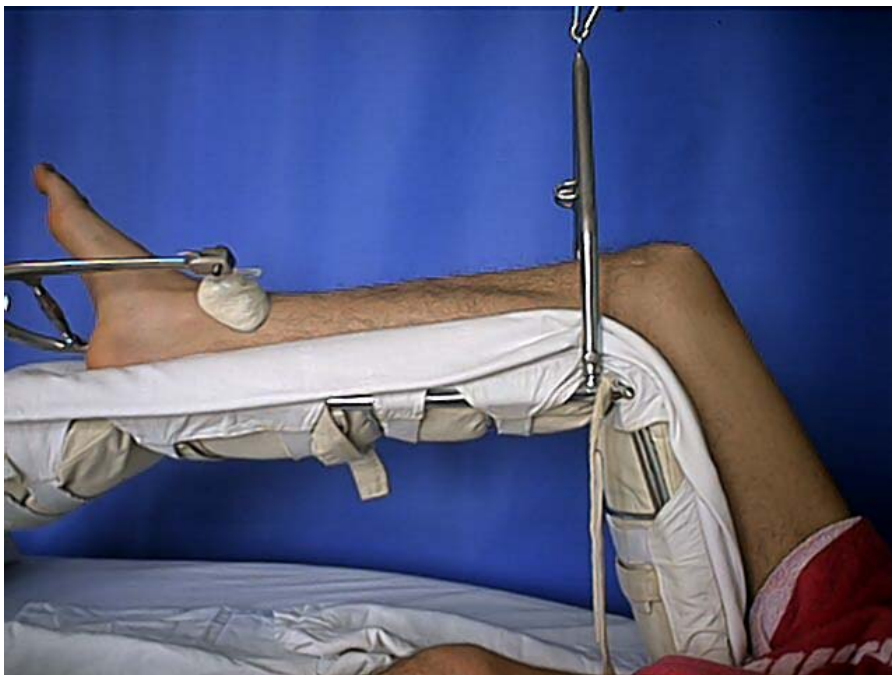
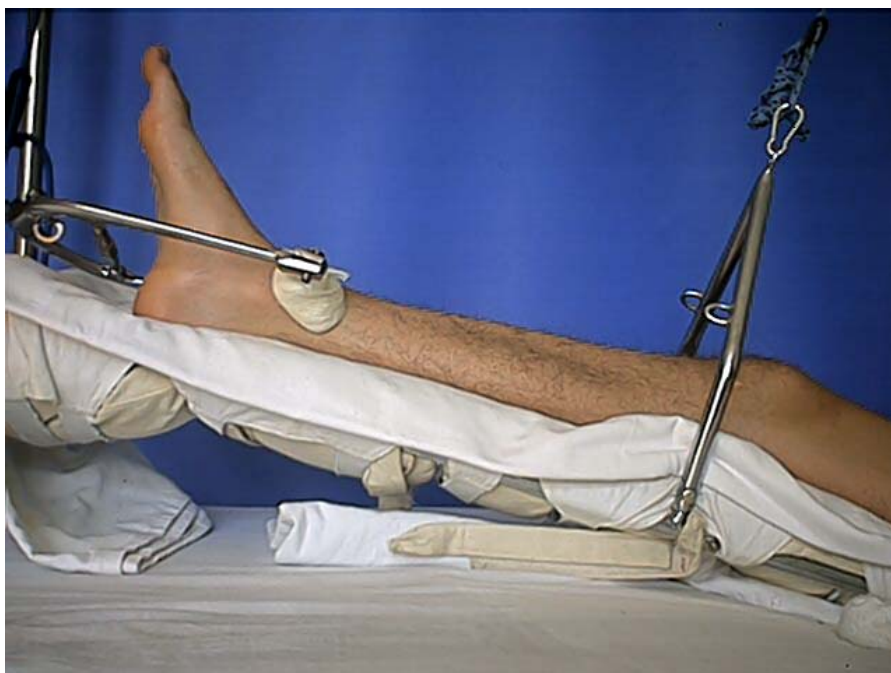Fig. 2. DHS (Dynamic Hip Screw) after operation of trochanteric fracture



a)



b)

Fig. 3. Functional therapy (skeletal traction and Müller's functional splint), a) flexion, b) extension

The study consists in goniometric measurement of the range of hip joint flexion mobility in the sagittal plane, taken on the third, seventh and fourteenth day after the beginning of rehabilitation. In the case of traction therapy, the measuring period began after removal of traction. Measurements were taken in patient's straightened bed in back position according to assumed standards. The measuring error was equal to 5° . The patients qualified to investigation lay in the same type of orthopaedic bed in order to ensure the same conditions of measurements.

4. Analysis results

Women were assigned to one of four groups consisting of six persons and examined three times. Angular values obtained in separate groups are averaged to get a characteristic value for each day and each group.

The investigation time was chosen in accordance with work organisation at Orthopaedic Department, Wrocław Medical University. On the third day after operation, which was also the third day after the beginning of mobilisation – rehabilitation (zero twenty-four hours – operation day) drain was removed and the patient was transported from recovery room to traumatic division. Drain removal and return to traumatic division favoured realisation of rehabilitation process and brought about similar conditions of measurement as in case patients were not subjected to

operation and stayed in the same sick room from beginning of their rehabilitation. The choice of the fourteenth day after the beginning of rehabilitation to carry out measurement was connected with the day of discharge of patients subjected to implantation of endoprosthesis. In the case of patients subjected to traction therapy their mobilisation begins with tractor removal. For this group of patients the fourteenth day was the last day of hospitalisation. The third and the second measurements of flexion range of hip joint in the sagittal plane were taken on the seventh day after the beginning of rehabilitation, which is half of the fourteen-day rehabilitation in the above two groups. For examination, patients with fracture of the proximal part of femur were purposefully chosen, comprising those after implantation of femoral prosthesis done with cement, after using of DHS system, after functional therapy and traction therapy, because this gives different possibilities of comparing these methods of treatment based on measurement results:

- comparison of operative and conservative therapy after fracture of the upper part of femur,
- comparison of two different treatment methods after fracture of the femoral neck (alloplasty, functional therapy),
- comparison of two different treatment methods after trochanteric fractures (DHS system, traction therapy),
- comparison of treatment methods after fracture of the femoral neck and after trochanteric fracture.

In each method of treatment, the passive range of flexion in hip joint in sagittal plane was considerably larger than active range of mobility, but active range was the subject of the study since locomotion depends on it.

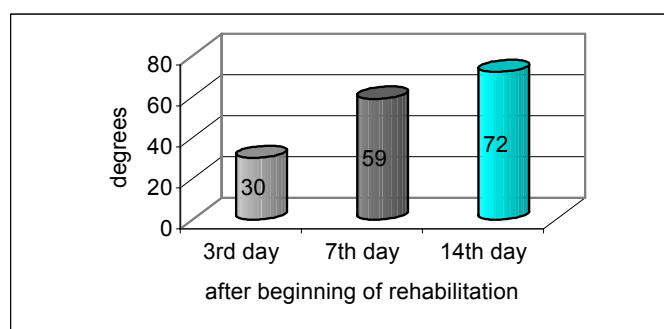


Fig. 4. The range of active flexion of limb in hip joint in sagittal plane in group I (alloplasty)

In the group of patients subjected to implantation of Austin-Moore's endoprosthesis, average range of active flexion in hip joint in sagittal plane on the third day after the beginning of rehabilitation was 30° (figure 4). All patients examined were tilted up and started to move with the help of a walker and crutches. It was impossible to achieve larger measurement value, because of painfulness in the surgical wound area. Angular value of flexion in hip joint in sagittal plane rose about 29° and

was 59° on the seventh day after the beginning of mobilisation. The patients moved by themselves using crutches in that period. Active flexion was 72° on the fourteenth day and passive flexion was similar to physiological one.

In patients from group II subjected to functional therapy with the use of skeletal tractor and functional splint, on the third day after the beginning of rehabilitation because of spontaneous painfulness in fractured area only a trace of movement was observed, which was not measured (figure 5). Painfulness connected with the movement in hip joint appeared at a flexion of 30° . In the next examination (the fourteenth day) painfulness during movement was not confirmed and flexion of hip joint was 49° .

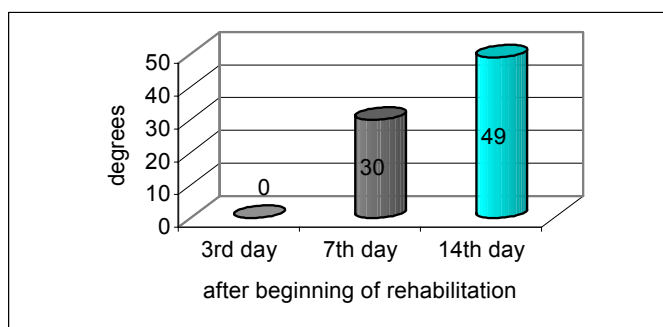


Fig. 5. The range of active flexion of limb in hip joint in sagittal plane in group II (functional therapy)

Patients from group III treated with DHS system during the first examination, on the third day of mobilisation were not able to demonstrate active flexion in hip joint (figure 6). Only a trace of movement was noticed. During the second measurement flexion the joint attained a value of 42° . At that time, the patients sat in bed with the lower limb drooped and did all exercises in area of bed in closed kinematic chains. This group of patients achieved flexion of about 60° on the fourteenth day of mobilisation.

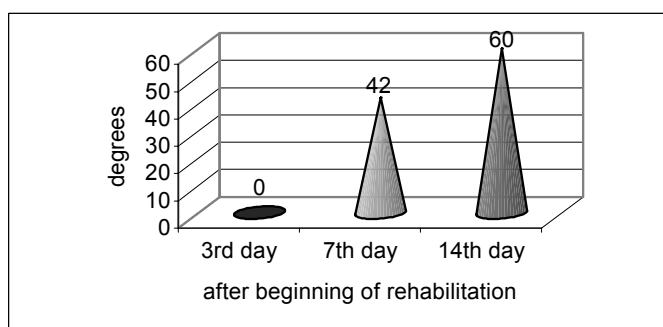


Fig. 6. The range of active flexion of limb in hip joint in sagittal plane in group III (DHS system)

In group IV, where patients were treated with the use of skeletal tractor, active flexion of hip joint in sagittal plane was 15° on the third day of rehabilitation (figure 7). Some difficulties observed during movement were connected with long-term immobilisation of fractured limb and with no movement of hip and knee joint. Active range of hip joint flexion was 35° on the seventh day and 45° on the fourteenth day. After tractor removal exercises in the group were done in closed kinematics chains.

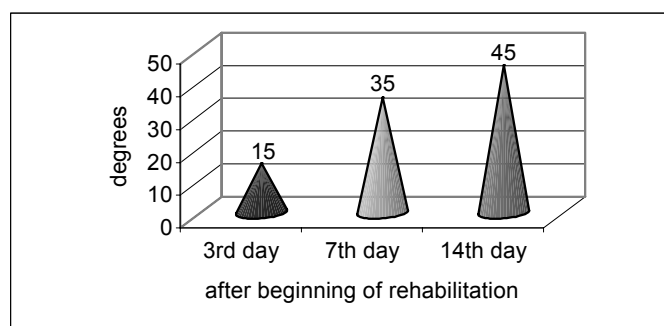


Fig. 7. The range of active flexion of limb in hip joint in sagittal plane in group IV (traction therapy)

The results obtained confirm greater usefulness of surgical procedure as regards the limb function. This situation seems to be mainly connected with mobility in sagittal plane. Active flexion of hip joint in the case of operative therapy (72° – alloplasty, 60° – DHS) was considerably greater than during conservative therapy. Similar results were obtained when comparing the operative and conservative therapy after the fracture of femoral neck (72° , 49°) and also after trochanteric fracture (60° , 45°).

The results show that owing to the available facilities the treatment of femoral neck fracture gives greater values of hip joint flexion in the early period of mobilisation (rehabilitation) than treatment of trochanteric fracture.

The clinical observation shows that obtained ranges of mobility give satisfactory functioning of patient in area of bed and out of bed.

5. Conclusions

1. The shortest time of regaining active mobility in sagittal plane was recorded in the group of patients after implantation of endoprosthesis, then after DHS use and next in the course of functional therapy. It took the longest time to regain active mobility in the group treated by traction.

2. Regaining active mobility in sagittal plane analogous to that described in point 1 determines physical fitness in area of bed and useful locomotion (locomotion and self-dependence).

References

- [1] ALUSIO F., CHRISTENSEN C., URBANIAK J., *Ortopedia*, Urban & Partner, Wrocław, 2000, 145–9.
- [2] CUMMING S.R., RUBIN S.M., BLACK D., *The femur fracture of hip in the United States: numbers and cost and potential effects of postmenopausal estrogen*, *Clin. Orthop.*, 1990, (252), 163–6.
- [3] ETHANS K., MACKNIGHT K., *Hip fracture in elderly*, *Postgraduate Med.*, 103, 1, 157–66.
- [4] GERBER C., STREHLE J., GANZ R., *The treatment of fractures of the femoral neck*, *Clin. Orthop.*, 1993, (292), 77–86.
- [5] KYLE R.F., CABENELA M.E., RUSSELL T.A., *Fractures of the proximal part of femur*, *J. Bone Joint Surg (Am)*, 1994, 76, 926–49.
- [6] LU-YAO G.L., BARON J.A., BERRETT J.A., *Treatment and survival among elderly American with hip fracture: a population-based study*, *Am. J. Public Health*, 1994, 8(4), 1287–91.
- [7] OCHS M., *Surgical management of the hip in the elderly patient*, *Clin. Geriatr. Med.*, 1990, 6(3), 571–87.
- [8] PALCZEWSKI D., MARCZUK M., SZYMAŃSKI W., *Własne doświadczenia w rehabilitacji chorych leczonych protezoplastyką połowiczą Austin–Moore’a z powodu złamań szyjki kości udowej*, *Chir. Narz. Ruch. Ortop. Pol.*, 1997, LXII, 5.
- [9] SIDOROWICZ J., GAŹDZIK T., JAWORSKI J.T., *Leczenie zachowawcze złamań okółokrętarzowych u osób w podeszłym wieku*, *Wiad. Lek.*, 1998, 51, 9–10.
- [10] WĄSIKOWSKI A., KORSZYŃSKI M., GĘSICH R., *Alloplastyka połowicza Moore’a w leczeniu złamań szyjki kości udowej*, *Chir. Narz. Ruch. Ortop. Pol.*, 1994, LIX, 1.