



Assessment of the lower limb biomechanics in patients after tibiofibular syndesmosis injury treatment

KRZYSZTOF KLEPACKI¹, IGOR KOWAL¹, GRZEGORZ KONIECZNY², ŁUKASZ TOMCZYK³,
MARIUSZ CISZEWSKI⁴, PAWEŁ REICHERT⁵, PIOTR MORASIEWICZ^{4*}

¹ Provincial Specialist Hospital in Legnica, Orthopedic Surgery Department, Legnica, Poland.

² Faculty of Health Sciences and Physical Education, The Witelton State University of Applied Sciences in Legnica, Legnica, Poland.

³ Department of Food Safety and Quality Management, Poznań University of Life Sciences, Poznań, Poland.

⁴ Department of Orthopaedic and Trauma Surgery, Institute of Medical Sciences, University of Opole, Opole, Poland.

⁵ Wrocław Medical University, Department of Trauma and Hand Surgery, Wrocław, Poland.

Purpose: There is no consensus as to the number of bone cortices engaged in tibiofibular syndesmosis treatment. The purpose of our study was to assess the weight distribution on the lower limbs after tricortical or quadricortical syndesmosis fixation and different timing of screw removal. *Methods:* A total of 55 patients who underwent treatment for acute tibiofibular syndesmosis injury were analyzed in this study. The Zebris pedobarographic platform was used to measure the distribution of body weight on the lower limbs. The study population was stratified by the time to syndesmotomic screw removal (8–15 weeks versus 16–22 weeks) and the number of bone cortices involved in fixation (three [tricortical fixation] versus four [quadricortical fixation]). *Results:* The weight distribution on the operated and healthy limbs in patients with tricortical syndesmosis fixation was asymmetrical, with the mean load on the operated and healthy limbs of 48.38% and 51.62%, respectively. The patients who underwent quadricortical syndesmosis fixation exhibited a symmetrical distribution of weight on the operated and healthy limb. There was a symmetrical distribution of the load of body weight on the operated and healthy limbs both in the group with different times to syndesmotomic screw removal. *Conclusion:* Tricortical syndesmosis fixation is associated with an asymmetrical weight distribution on the operated and healthy limbs. In treating tibiofibular syndesmosis injuries, based on our pedobarographic research, quadricortical syndesmosis fixation and leaving the syndesmotomic screw in place for up to 15 weeks, seems more beneficial to the patient.

Key words: symmetry, weight distribution, lower limbs, tibiofibular syndesmosis injury, pedobarographic platform

1. Introduction

Isolated tibiofibular syndesmosis injuries occur in 5% to 10% of all ankle joint injuries, with the proportion rising up to 23% when the tibiofibular syndesmosis is injured in association with adjacent bone fracture [2], [7], [11], [20]–[22], [25], [27].

Traumatic tibiofibular syndesmosis disruption adversely affects the anatomy and biomechanics of the ankle joint [2], [4]–[7], [11], [21], [22], [25], [27] by making it unstable, which leads to pain, limited function, limited range of motion, and joint structure

degeneration over time [2], [4]–[7], [11], [21], [22], [25], [27].

The treatment goal in tibiofibular syndesmosis injury is to restore ankle joint anatomy and normal biomechanical properties, reduce pain, and improve the range of motion [2], [4]–[7], [11], [21], [22], [25], [27].

There have been a number of reports on various treatment methods for tibiofibular syndesmosis injuries that involve screw placement [2], [5]–[7], [11], [20]–[22], [25], [27], however, there is no consensus as to the number of bone cortices engaged or the time to screw removal [2], [4]–[7], [11], [21], [22], [25], [27].

* Corresponding author: Piotr Morasiewicz, Wrocław Medical University, Department of Trauma and Hand Surgery, ul. Borowska 213, 50-556 Wrocław, Poland. E-mail: morasp@poczta.onet.pl

Received: October 23rd, 2021

Accepted for publication: December 20th, 2021

Some orthopedic surgeons advocate tricortical syndesmosis fixation by arguing that it reduces the time to weight-bearing after surgery, provides a more dynamic fixation, eliminates the need for screw removal and reduces the risk of broken screws [4]–[7], [20], [27]. Other surgeons consider quadricortical syndesmosis fixation to be the method of choice due to a better stability of the ankle joint and the possibility of achieving a more accurate restoration of ankle joint anatomy [5], [7], [22]. Some surgeons remove the syndesmotomic screw after 8 weeks [4], [20], [21], some after 12 weeks [4], and some after 16–20 weeks [24].

Physiologically, the load of body weight should be distributed symmetrically or nearly symmetrically on the two lower limbs [1], [3], [8], [9], [12]–[19], [23], [26]. A normal, nearly symmetrical weight distribution is associated with normal joint mobility and stability, the absence of pain, and normal limb function [1], [3], [8], [9], [12]–[19], [23], [26]. To date, there have been studies assessing the effect of various musculoskeletal pathologies on the distribution of body weight on the lower limbs with the use of a pedobarographic platform [3], [8], [9], [12]–[19], [26]. Tests using the pedobarographic platform are repeatable, objective, non-invasive for the patient, not burdensome, and quick to perform [3], [8], [9], [12]–[17], [19], [26]. The results of the new research can be compared with the reports of other authors.

However, the effects that the length of time syndesmotomic screws remain in place and the number of the cortices involved in fixation may have on lower limb biomechanics have not been evaluated.

The results of tibiofibular syndesmosis injury treatment should be comprehensively assessed not only in terms of the clinical and radiographic outcomes but also biomechanical properties of the affected structures [5], [7], [20], [22], [24], [25], [27]. Correction of tibiofibular syndesmosis is routinely assessed on the basis of TF (tibiofibular) overlap, TF diasthesis, and ankle joint asymmetry, also perform a CT scan [5], [7], [20], [22], [24], [25], [27]. There are no studies describing the biomechanics of the ankle joint after this type of injury.

We hypothesized that in tibiofibular syndesmosis injuries treated with screw fixation both the time to syndesmotomic screw removal and the number of the engaged cortices affect lower limb biomechanics (body weight distribution). Theoretically, longer screw maintenance and quadricortical syndesmosis fixation allow for more stable stabilization of the ligament. On the other hand, patients more often report reduced dorsiflexion in the ankle joint. This may generate a reluctance to fully load the limb and thus affect the biomechanics of the ankle joint.

The purpose of our study was to assess the weight distribution on the two lower limbs after treatment of tibiofibular syndesmosis injury.

2. Materials and methods

A total of 55 patients who underwent treatment for tibiofibular syndesmosis injury at our orthopedics department were analyzed in this retrospective study. There were 37 female and 18 male, height of 165–190 cm, weight of 50–110 kg and BMI of 17–40. The inclusion criteria were a tibiofibular syndesmosis injury treated at our department, an unstable Webber B or C fracture with a concomitant tibiofibular syndesmosis injury, as those requiring surgery. Trauma radiographs revealed features of tibiofibular ligament damage, such as decreased TF overlap < 10 mm, increased TF diasthesis > 5mm and an ankle joint asymmetry above 2 mm [5], [7], [20], [22], [24], [25], [27]. The inclusion criteria were: being at least 2 years after treatment completion, having complete clinical and radiographic records, available pedobarographic assessment results, absence of other lower limb pathologies, absence of neurologic abnormalities and a written informed consent.

The exclusion criteria were: a tibiofibular syndesmosis injury treated elsewhere, no unstable Webber B or C fracture with a concomitant tibiofibular syndesmosis injury, a post-treatment follow-up of less than 2 years, incomplete clinical and radiographic records, unavailable or absent pedobarographic assessment results, additional lower limb pathologies, neurologic abnormalities; no informed consent, bilateral ankle joint injury. Total number of excluded patients from initially chosen group was 96.

The study was conducted in accordance with the Declaration of Helsinki and the protocol was approved by the Bioethics Committee at the Lower Silesian Medical Chamber in Wrocław (1/PNDR/2021). All subjects provided their written informed consent having been informed that study participation was entirely voluntary and they could withdraw from the study at any time. Application of the inclusion and exclusion criteria resulted in 55 patients (37 females and 18 males), aged from 25 to 75 years, being ultimately included in the study. The period of follow-up from treatment completion to the follow-up assessment ranged from 2 years to 4 years and 2 months.

The study population was stratified by the time to syndesmotomic screw removal (8–15 weeks versus 16–22 weeks) and the number of bone cortices in-

volved in fixation (three [tricortical fixation] versus four [quadricortical fixation]).

The 8–15-week subgroup comprised 19 patients, and the 16–22-week subgroup comprised 36 patients. There were 21 patients with tricortical and 34 patients with quadricortical syndesmosis fixation of their tibiofibular syndesmosis injury.

Unstable Webber B and C fractures with concomitant tibiofibular syndesmosis injury were qualified for open reduction and internal fixation. The surgical procedures were performed with the use of C-arm fluoroscopy. The fracture was exposed with a lateral incision over the fibula, reduced, and preliminarily fixed with a Kirschner wire (K-wire). After the bone fragments had been properly repositioned, the fibular fracture was permanently fixed with an anatomic plate. Subsequently, the tibiofibular syndesmosis was repositioned and fixed with a screw. At that time – depending on bone quality, the character of fracture and tibiofibular syndesmosis injury and individual preferences – the surgeon decided to use either tricortical or quadricortical fixation of the disrupted tibiofibular syndesmosis with a 3.5 mm screw. All the procedures were performed by one of three orthopedic surgeons. Adequate reduction of the syndesmosis were confirmed in C-arm fluoroscopy and postsurgical radiographs for all patients.

During the postoperative period, patients walked with the use of two forearm crutches, with reduced weight bearing on the operated limb and were recom-

mended to maintain mobility in their ankle joint. At 6 weeks after the procedure, bone union was assessed radiographically and the patients were referred for rehabilitation and syndesmotomic screw removal. Depending on the radiographic status, the patient was allowed to bear increasingly more weight on the operated limb until full weight bearing. Also, depending on the status of the operated ankle, operating room availability and patient's personal schedule, the procedure of syndesmotomic screw removal was scheduled and performed within one of the above time ranges after the initial procedure. All patients underwent the same rehabilitation regimen.

An 320 × 470 mm, 1,504-sensor pedobarographic platform (Zebris Medical GmbH) was used to measure the distribution of body weight on the lower limbs (Fig. 1). The platform, which is connected via a USB port with a computer with FootPrint (ver. 1.2.4.9.) software, makes it possible to analyze static and dynamic (during gait) force distribution in two and three dimensions.

The following parameters were measured: total load on the operated limb [%]; total load on the healthy limb [%]; forefoot load in the operated limb [%]; forefoot load in the healthy limb [%]; hindfoot load in the operated limb [%]; hindfoot load in the healthy limb [%]. The collected data were used in a statistical analysis.

Prior to pedobarometric measurements, each patient was informed of the purpose of the assessment and

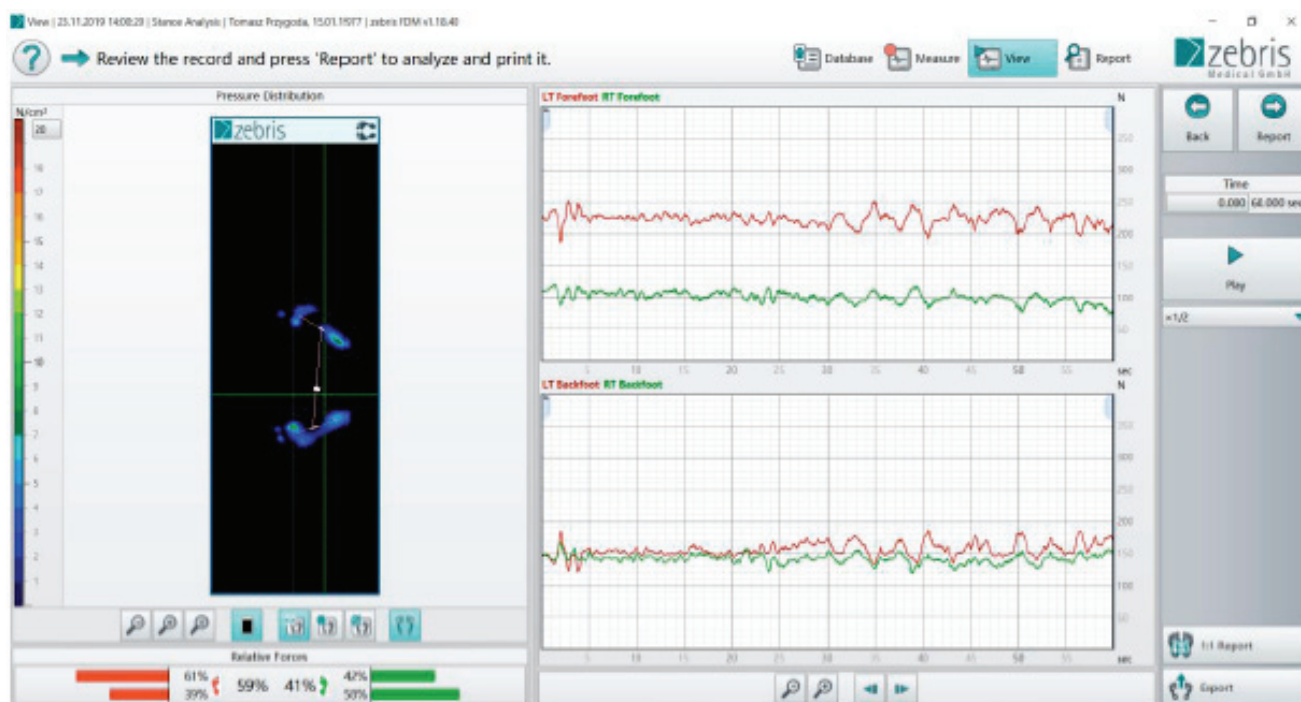


Fig. 1. The distribution of body weight on the lower limbs from the pedobarographic platform

familiarized with the function of the pedobarographic platform. The platform was calibrated prior to each measurement.

The patients were assessed barefoot, with their eyes open, over a period of 60 seconds. Each patient stood on the platform motionless in a neutral position, with the feet hip-width apart. The measurements were conducted three times for each patient, with the mean value from the three attempts used for further analyses.

We evaluated the differences between the groups depending on the time to syndesmotomic screw removal and the number of bone cortices engaged in fixation.

The obtained data were statistically analyzed using 13.3 software (StatSoft, Tulsa, Oklahoma, USA). The Shapiro–Wilk test was used to check for normality of distribution. All values are expressed as the mans and standard deviation. For comparisons of variables, the unpaired Student’s *t*-test or the Mann–Whitney *U*-test were used depending on the type of distribution. The level of statistical significance was set at $p < 0.05$.

3. Results

The weight distribution on the operated and healthy limbs in patients with tricortical syndesmosis fixation was asymmetrical, with the mean load on the operated and healthy limbs of 48.38 and 51.62%, respectively; the difference was statistically significant ($p = 0.0213$) (Table 1, Figs. 2, 3).

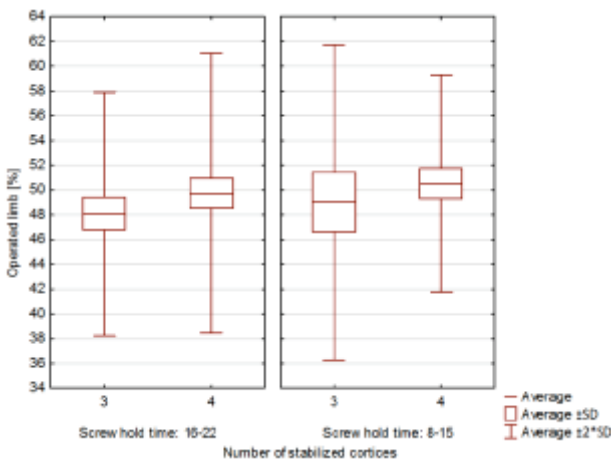


Fig. 2. Weight distribution on the operated limb

The patients who underwent quadricortical syndesmosis fixation exhibited a symmetrical distribution of weight on the operated and healthy limb, with a mean of 50%; the difference was not significant (Table 1, Figs. 2, 3).

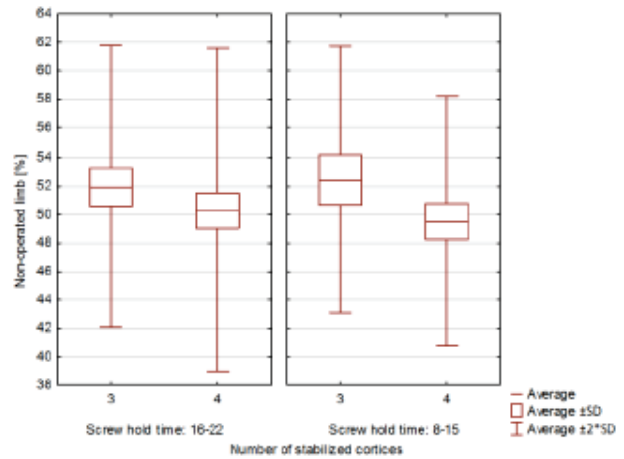


Fig. 3. Weight distribution on the healthy limb

The tricortical or quadricortical syndesmosis fixation subgroups showed no significant differences in weight distribution on the forefoot or hindfoot in the operated and healthy limbs (Table 1).

Table 1. Body weight distribution for patients after treatment with 3 and 4 stabilized cortices

Tests performed for 60 seconds with participants open eyes		
Loads on limb	3 cortices (n = 21)	4 cortices (n = 34)
Operated limb [%]	48.38 ± 10.42	50 ± 12.32
Non-operated limb [%]	51.62 ± 9.63	50 ± 10.32
<i>P</i>	0.0213	1
Forefoot OL [%]	40.76 ± 13.32	42.41 ± 12.83
Forefoot NOL [%]	38.95 ± 11.21	42.49 ± 11.65
<i>P</i>	0.6558	0.993
Backfoot OL [%]	59.23 ± 12.01	57.58 ± 10.32
Backfoot NOL [%]	61.04 ± 11.41	57.5 ± 12.41
<i>P</i>	0.655	0.9789

Data are mean ± standard deviation, OL – operated limb, NOL – non operated limb.

Moreover, a comparison between the two treatment groups in terms of total load and load distribution on the two limbs showed no significant differences (Table 2).

There were no statistically significant differences of distribution of the load of body weight on the operated and healthy limbs both in the group where the time to syndesmotomic screw removal was 8–15 weeks and in the group where the screw remained in place for 16–22 weeks (Table 3).

There were no significant differences in measurement results comparing the weight distribution on the forefoot or hindfoot in the operated and healthy limbs between the 8–15-week and the 16–22-week syndesmotomic screw groups (Table 3).

Table 2. Body weight distribution for patients after treatment with 3 stabilized cartable 4 stabilized cortices

Tests performed for 60 seconds with participants open eyes			
Loads on limb	3 cortices (n = 21)	4 cortices (n = 34)	P
Operated limb [%]	48.38 ± 11.32	50 ± 10.96	0.2692
Non-operated limb [%]	51.62 ± 12.41	50 ± 11.42	0.1377
Forefoot OL [%]	40.76 ± 10.21	42.41 ± 8.96	0.5821
Forefoot NOL [%]	38.95 ± 7.56	42.49 ± 9.52	0.3541
Backfoot OL [%]	59.23 ± 9.23	57.58 ± 9.74	0.6436
Backfoot NOL [%]	61.04 ± 9.64	57.5 ± 10.36	0.3951

Data are mean ± standard deviation, OL – operated limb, NOL – non operated limb.

Table 3. Body weight distribution for patients after treatment with screw hold time 8–15 weeks and 16–22 weeks

Tests performed for 60 seconds with participants open eyes		
Loads on limb	8–15 weeks (n = 19)	16–22 weeks (n = 36)
Operated limb [%]	49.94 ± 5.07	49.08 ± 4.57
Non-operated limb [%]	50.06 ± 5.36	50.91 ± 5.36
P	0.6892	0.1518
Forefoot OL [%]	39.26 ± 12.05	43.11 ± 15.72
Forefoot NOL [%]	40.26 ± 12.76	41.44 ± 13.75
P	0.8271	0.5151
Backfoot OL [%]	60.73 ± 12.05	56.88 ± 15.72
Backfoot NOL [%]	59.73 ± 11.32	58.55 ± 10.25
P	0.8271	0.5939

Data are mean ± standard deviation, OL – operated limb, NOL – non operated limb.

Similarly, there were no significant differences in the total load on each limb or load distribution between the groups with different times to syndesmotomic screw removal (Table 4).

Table 4. Body weight distribution for patients after treatment with screw hold time 8–15 weeks compared to 16–22 weeks

Tests performed for 60 seconds with participants open eyes			
Loads on limb	8–15 weeks (n = 19)	16–22 weeks (n = 36)	P
Operated limb [%]	49.94 ± 5.07	49.08 ± 5.36	0.5655
Non-operated limb [%]	50.06 ± 5.36	50.91 ± 4.57	0.8167
Forefoot OL [%]	39.26 ± 12.05	43.11 ± 12.76	0.2507
Backfoot OL [%]	60.73 ± 12.05	56.88 ± 12.96	0.2889
Forefoot NOL [%]	40.26 ± 15.76	41.44 ± 13.75	0.7132
Backfoot NOL [%]	59.73 ± 15.76	58.55 ± 13.43	0.7712

Data are mean ± standard deviation, OL – operated limb, NOL – non operated limb.

4. Discussion

Tibiofibular syndesmosis injuries pose a considerable social problem due to their high incidence [2], [5]–[7], [12], [20]–[22], [25], [27]. There is no consensus among orthopedic surgeons as to which fixation method is optimal for treating disrupted tibiofibular syndesmoses [2], [5]–[7], [12], [20]–[22], [25], [27].

Tibiofibular syndesmosis injuries alter the anatomy and biomechanics of the ankle joint and result in an uneven distribution of body weight on lower limbs [2], [4]–[7], [11], [21], [22], [24], [25], [27]. A rapid and effective treatment of tibiofibular syndesmosis injuries is necessary to restore the normal joint biomechanics and function [2], [4]–[6], [11], [21], [22], [25], [27].

A symmetrical body weight distribution on the two lower limbs reflects good treatment outcomes of lower limb pathologies [1], [3], [8], [9], [12]–[19], [23], [26]. Improved joint mobility, including mobility of the ankle joint, pain reduction or complete alleviation, reduced joint instability and improved joint function lead to symmetrical body weight distribution on both limbs [1], [3], [8], [9], [12]–[19], [23], [26].

Individual orthopedic surgeons differ in terms of their preferred fixation technique in treating tibiofibular syndesmosis injuries [2], [6], [20], [22]. Some surgeons choose tricortical syndesmosis fixation [6], whereas others prefer quadricortical syndesmosis fixation [2], [5], [22].

The advocates of tricortical syndesmosis fixation argue that it allows for weight-bearing sooner after the surgery, constitutes a more dynamic fixation, reduces limitations in the range of motion at the ankle joint, does not necessitate screw removal, and carries a lower risk of broken screws than the quadricortical method [2], [4]–[6], [20], [27]. Moreover, the use of tricortical syndesmosis fixation does not require a second surgery, which carries a risk of complications and increases the cost of treatment and the number of days the patient is away from work [5], [6], [27]. In contrast, those surgeons who consider quadricortical syndesmosis fixation to be their method of choice argue that it ensures a better stability of the ankle joint, possibility to restore the ankle joint in a more anatomically accurate way, and – in the case of a broken screw – an easier screw removal due to the end of the screw protruding beyond the surface of the tibia [2], [6], [22].

Opinions are also divided in terms of the optimal time to syndesmotomic screw removal, [2], [5], [20], [21], [24] with some orthopedic surgeons removing the screw

after 8 weeks [4], [20], [21], some after 12 weeks [4], and some after 16–20 weeks [24].

Our study assessed the, as of yet unexplored, impact of the time to syndesmotic screw removal and the number of bone cortices involved on the weight distribution on the lower limbs.

According to relevant literature, the complications that might affect the symmetry of weight distribution occur in 12–31% of patients following tibiofibular syndesmosis injury [5], [22], [27].

Lorkowski et al. [20] pedobarographically assessed underfoot pressure distribution in a patient with unilateral talonavicular joint ankylosis and observed an improved pressure distribution following orthopedic treatment and pain reduction [20].

Earlier studies assessed the load put on the lower limbs in patients after Ilizarov method osteotomy procedures [12], [15], Ilizarov method ankle joint arthrodesis procedures [14], [13] and tibial nonunion treatment [17]. After treatment completion, the load of body weight was reported to be symmetrical in the two lower limbs [12]–[15], [17]. The patients after lower limb Ilizarov method osteotomy put a similar load on their limbs as that observed in healthy individuals [12]. Pawik et al. [17] observed a symmetrical body weight distribution in lower limbs over the entire foot surface, as well as in the hindfoot and forefoot, following tibial nonunion treatment. The pedobarography results obtained for the study group were similar to those obtained in healthy volunteers [17].

Schepers et al. [20] reported no differences in the clinical and functional assessment results, irrespectively of the time period to syndesmosis screw removal. The patients from both of our study groups with different time periods to syndesmosis screw removal had a symmetrical weight distribution on the lower limbs, both in terms of the total load and load distribution over the forefoot and hindfoot. This indicates that leaving a syndesmotic screw in place for over 15 weeks is not warranted.

Schepers et al. [20] reported no differences between the evaluated patients from the tricortical and quadricortical syndesmosis fixation groups in terms of either the functional scale scores or visual analog scale scores of pain. The patients assessed by Hoiness and Stromsoe showed no differences between the tricortical and quadricortical syndesmosis fixation groups in terms of pain, dorsiflexion, or functional scores [4]. Markolf et al. [10] reported no differences between the tricortical and quadricortical syndesmosis fixation on biomechanics of the ankle joint.

Our assessment of weight distribution on lower limbs revealed the results to be more symmetrical in

the quadricortical syndesmosis fixation group. In that group, the load of body weight put on the operated and healthy limb was exactly 50% each. The tricortical syndesmosis fixation group showed a lack of symmetry between the load placed on the operated and healthy limbs, with the operated limb bearing less weight than the healthy one. In theory, this may adversely affect joint mobility, cause pain, and impair joint stability in the future [1], [8], [9], [12]–[17], [23]. The two groups of patients distinguished by the number of bone cortices involved in syndesmosis fixation showed comparable weight distribution on the forefoot and hindfoot. These results were consistent with those reported in earlier studies on weight distribution on lower limbs [9], [12]–[17]. Due to our study the quadricortical syndesmosis fixation method seems to be a slightly better treatment choice in terms of improved weight distribution and lower limb biomechanics.

One limitation of our study is its retrospective nature, however, due to the unexpected character of injuries, it was impossible to assess the patients prior to their tibiofibular syndesmosis injury treatment. Moreover, most studies on tibiofibular syndesmosis injuries are also retrospective [11], [21], [24]. Another limitation of our study was the assessment of only the static parameters. In subsequent studies we are planning to assess the gait of patients after tibiofibular syndesmosis injury treatment. The strengths of our study include the fact that all procedures were performed by one of three orthopedic surgeons, the rehabilitation regimen was the same for all patients, and the assessed parameters were measured with an established objective tool, which was the pedobarographic platform [3], [9], [12]–[17], [26]. In the future, we plan to extend our research to the study of ranges of motion in patients divided into the same groups as in this study. In the future, we plan to conduct a study on a larger number of patients.

5. Conclusions

Tibiofibular syndesmosis injury patients put their weight symmetrically on both lower limbs after treatment, irrespectively of the time to syndesmosis screw removal. Tricortical syndesmosis fixation is associated with an asymmetrical weight distribution on the operated and healthy limbs. All study subgroups showed a symmetrical distribution of the forefoot load and hindfoot load in the two lower limbs. In treating tibiofibular syndesmosis injuries, based

on our pedobarographic research, quadricortical syndesmosis fixation and leaving the syndesmotom screw in place for up to 15 weeks, seems more beneficial to the patient. Standardization of the treatment process of tibiofibular syndesmosis injury can make it possible to achieve better treatment results and create a rehabilitation algorithm that will more accurately respond to the needs of patients.

References

- [1] BHAVE A., PALEY D., HERZENBERG J.E., *Improvement in gait parameters after lengthening for the treatment of limb-length discrepancy*, J. Bone Jt. Surg., Ser A, 1999, 81, 529–34.
- [2] FORT N.M., AIYER A.A., KAPLAN J.R., SMYTH N.A., KADAKIA A.R., *Management of acute injuries of the tibiofibular syndesmosis*, Eur. J. Orthop. Surg. Traumatol., 2017, May, 27 (4), 449–459, DOI: 10.1007/s00590-017-1956-2.
- [3] GIMUNOVA M., SKOTÁKOVÁ A., GRÜN V., JENČIKOVÁ K., DANĚK L., HLINSKY T., SVOBODOVÁ L., KALICHOVÁ M., VÁLKOVÁ H., *The differences in postural stability between cross-country and Alpine skiers with intellectual disabilities*, Acta Bioeng. Biomech., 2020, 22 (4), 133–138.
- [4] HØINNESS P., STRØMSØE K., *Tricortical versus quadricortical syndesmosis fixation in ankle fractures: a prospective, randomized study comparing two methods of syndesmosis fixation*, J. Orthop. Trauma, 2004 Jul, 18 (6), 331–337, DOI: 10.1097/00005131-200407000-00001.
- [5] KAFTANDZIEV I., SPASOV M., TRPESKI S., ZAFIROVA-IVANOVSKA B., BAKOTA B., *Fate of the syndesmotom screw – Search for a prudent solution*, Injury, 2015, Nov., 46 Suppl. 6, S125-9, DOI: 10.1016/j.injury.2015.10.062.
- [6] LALLI T.A.J., MATTHEWS L.J.M., HANSELMAN A.E., HUBBARD D.F., BRAMER M.A., SANTROCK R.D., *Economic impact of syndesmosis hardware removal*, Foot, 2015, Sep., 25 (3), 131–133, DOI: 10.1016/j.foot.2015.03.001.
- [7] LI H., CHEN Y., QIANG M., ZHANG K., JIANG Y., ZHANG Y., JIA X., *Computational biomechanical analysis of postoperative inferior tibiofibular syndesmosis: a modified modeling method*, Comput. Methods Biomech. Biomed. Engin., 2018 Apr, 21 (5), 427–435, DOI:10.1080/10255842.2018.1472770.
- [8] LORKOWSKI J., TRYBUS M., HŁADKI W., BRONGEL L., *Underfoot pressure distribution of a patient with unilateral ankle arthrodesis of talonavicular joint during rheumatoid arthritis – case report*, Przegl. Lek., 2008, 65, 54–56.
- [9] MAJEWSKI M., BISCHOFF-FERRARI H.A., GRÜNEBERG C., DICK W., ALLUM J.H.J., *Improvements in balance after total hip replacement*, J. Bone Jt. Surg., Ser B, 2005, 87, 1337–1343.
- [10] MARKOLF K., JACKSON S.R., MCALLISTER D.R., *Syndesmosis fixation using dual 3.5 mm and 4.5 mm screws with tricortical and quadricortical purchase: a biomechanical study*, Foot Ankle Int., 2013, 34, 734–739.
- [11] MCKENZIE A.C., HESSELHOLT K.E., LARSEN M.S., SCHMAL H., *A Systematic Review and Meta-Analysis on Treatment of Ankle Fractures With Syndesmotom Rupture: Suture-Button Fixation Versus Cortical Screw Fixation*, J. Foot Ankle Surg., 2019, Sep., 58 (5), 946–953, DOI: 10.1053/j.jfas.2018.12.006.
- [12] MORASIEWICZ P., DRAGAN S., DRAGAN S.Ł., WRZOSEK Z., PAWIK Ł., *Pedobarographic analysis of body weight distribution on the lower limbs and balance after Ilizarov corticotomies*, Clin. Biomech., 2016, 31, 2–6.
- [13] MORASIEWICZ P., KONIECZNY G., DEJNEK M., MORASIEWICZ L., URBAŃSKI W., KULEJ M., DRAGAN S.Ł., DRAGAN S.F., PAWIK Ł., *Pedobarographic analysis of body weight distribution on the lower limbs and balance after ankle arthrodesis with Ilizarov fixation and internal fixation*, Biomed. Eng. Online, 2018, 17, 174, DOI: 10.1186/s12938-018-0608-z.
- [14] MORASIEWICZ P., KONIECZNY G., DEJNEK M., URBAŃSKI W., DRAGAN S.Ł., KULEJ M., DRAGAN S.F., PAWIK Ł., *Assessment of the distribution of load on the lower limbs and balance before and after ankle arthrodesis with the Ilizarov method*, Sci. Rep., 2018, 8, 15693.
- [15] MORASIEWICZ P., URBAŃSKI W., KULEJ M., DRAGAN S.Ł., DRAGAN S.F., PAWIK Ł., *Balance and lower limb loads distribution after Ilizarov corticotomy*, Injury, 2018, 49, 860–865.
- [16] PAJCHERT-KOZŁOWSKA A., PAWIK Ł., SZELERSKI Ł., ŻAREK S., GÓRSKI R., PAWIK M., FINK-LWOW F., MORASIEWICZ P., *Assessment of body balance of patients treated with the Ilizarov method for tibial nonunion*, Acta Bioeng. Biomech., 2020, 22 (3), 131–137.
- [17] PAWIK Ł., PAJCHERT-KOZŁOWSKA A., SZELERSKI Ł., ŻAREK S., GÓRSKI R., PAWIK M., FINK-LWOW A., MORASIEWICZ P., *Assessment of Lower Limb Load Distribution in Patients Treated with the Ilizarov Method for Tibial Nonunion*, Med. Sci. Mon., DOI: 10.12659/MSM.930849.
- [18] RADLER C., KRANZL A., MANNER H.M., HÖGLINGER M., GANGER R., GRILL F., *Torsional profile versus gait analysis: Consistency between the anatomic torsion and the resulting gait pattern in patients with rotational malalignment of the lower extremity*, Gait Posture, 2010, 32, 405–410.
- [19] RONGIES W., BAŁ A., LAZAR A., DOLECKI W., KOLANOWSKA-KENCZEW T., SIERDZIŃSKI J. et al., *A trial of the use of pedobarography in the assessment of the effectiveness of rehabilitation in patients with coxarthrosis*, Ortop. Traumatol. Rehabil., 2009, 11, 242–252.
- [20] SCHEPERS T., LINDEN H. VAN DER, LIESHOUT E.M.M. VAN, NIESTEN D., ELST M. VAN DER, *Technical aspects of the syndesmotom screw and their effect on functional outcome following acute distal tibiofibular syndesmosis injury*, Injury, 2014, Apr., 45 (4), 775–779, DOI: 10.1016/j.injury.2013.09.035.
- [21] STIENE A., RENNER C.E., CHEN T., LIU J., EBRAHEIM N.A., *Distal Tibiofibular Syndesmosis Dysfunction: A Systematic Literature Review of Dynamic Versus Static Fixation Over the Last 10 Year*, J. Foot Ankle Surg., 2019 Mar, 58 (2), 320–327, DOI: 10.1053/j.jfas.2018.08.050.
- [22] STUART K., PANCHBHAVI V.K., *The fate of syndesmotom screws*, Foot Ankle Int., 2011 May, 32 (5), S519-25, DOI: 10.3113/FAI.2011.0519.
- [23] VEILLEUX L.N., ROBERT M., BALLAZ L., LEMAY M., RAUCH F., *Gait analysis using a force-measuring gangway: Intrasection repeatability in healthy adults*, J. Musculoskelet. Neuronal Interact., 2011, 11, 27–33.
- [24] WALKER L., WILLIS N., *Weber C ankle fractures: a retrospective audit of screw number, size, complications, and retrieval rates*, J. Foot Ankle Surg., May–Jun 2015, 54 (3), 454–457, DOI: 10.1053/j.jfas.2014.11.015.
- [25] WOOD A.R., ARSHAD S.A., KIM H., STEWART D., *Kinematic Analysis of Combined Suture-Button and Suture Anchor Augment Constructs for Ankle Syndesmosis Inju-*

- ries, *Foot Ankle Int.*, 2020 Apr, 41 (4), 463–472, DOI: 10.1177/1071100719898181.
- [26] YOUSSEF E.F., SHANB A.A., AMEER M.A., SHANAB M.E., *Impact of body weight on shifting of foot pressure among adult subjects*, *Acta Bioeng. Biomech.*, 2020, 22 (2), 131–137.
- [27] ZHANG P., LIANG Y., HE J., FANG Y., CHEN P., WANG J., *A systematic review of suture-button versus syndesmotic screw in the treatment of distal tibiofibular syndesmosis injury*, *BMC Musculoskelet. Disord.*, 2017 Jul, 4, 18 (1), 286, DOI: 10.1186/s12891-017-1645-7.