

## **Structure and operation of skeletal apparatus of authors own design for the repair of zygomatico-orbital fractures**

R. PELC, T. CIEŚLIK, M. HABELAK, M. ADWENT

Department of Maxillofacial Surgery, Silesian Academy of Medicine, Zabrze

Zygomatico-orbital fractures are a frequent sequel to trauma of the facial skeleton. The treatment of these fractures is various, depending on their clinical and radiological pictures. The authors describe these methods of positioning and immobilization of zygomatico-orbital fractures that have been used for years. In this context, the Jankowski's frame and its subsequent modifications should be mentioned. The paper presents the project and operation patterns of a framework device being designed by authors and used in reposition and fixation of zygomatico-orbital fractures. This device was successfully used in the treatment of 70 patients.

*Key words: zygomatico-orbital fractures, skeletal apparatus, bone reposition*

### **1. Introduction**

A method of percutaneous reposition of jugular bone with a single-toothed hook was pioneered in 1927 by Wassmund, and then modified by Rehrmann. Since that time, several types of single-toothed hooks, i.e. Duclos's, Freidle's, Limberg's, Langenbeck's, Stromayer's and Jankowski's hooks, have been used [6], [8], [11]. In many cases, the bone fragments repositioned with a hook tend to get replaced again. Therefore, we use hooks with disposable handles which are next mounted through skeletal apparatus on a plaster cap on the patient's head for the period of 6–8 days to fix the bone fragments [7], [8], [13]. In the Jędraszko's apparatus, the hook inserted under the jugular bone joins the metal bar and rubber rings, whose direction and tension can be freely adjusted. Kępiński repositioned the jugular bone with Limber's hook which was adjusted in Jędraszko's apparatus [7], [8]. This method brought many other constructions of skeletal apparatuses.

In 1957, at the Clinic of Maxillofacial Surgery (Teaching Hospital) in Zabrze, Jankowski introduced a skeletal apparatus made of thick, hard, stainless steel. It

consisted of a frame for mounting into a plaster cap, a vertical runner with slide control and a handle for mounting the hook [6] (figure 1). Its further modifications were made to change the ways of connecting each element with the hook [11], [13].

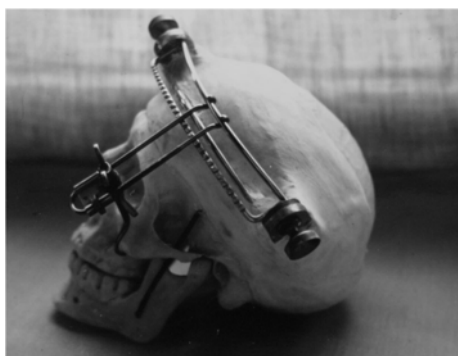


Fig. 1. Jankowski's skeletal apparatus

## 2. Experimental

Many year observations showed that the most serious problems occurred during mounting the hook on the apparatus and they stemmed from loosening the hook in the mounted unit. This inclined us to make our own modification of a skeletal apparatus. Moreover, we wanted our construction to be small and light. This apparatus has been used in the I Clinic of Maxillofacial Surgery in Zabrze since March 1996. It is made of tissue-neutral steel of the 2H28N9T symbol.

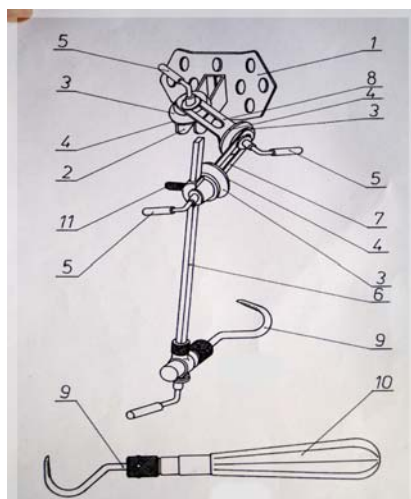


Fig. 2. Apparatus diagram.  
Single-toothed hook with a handle

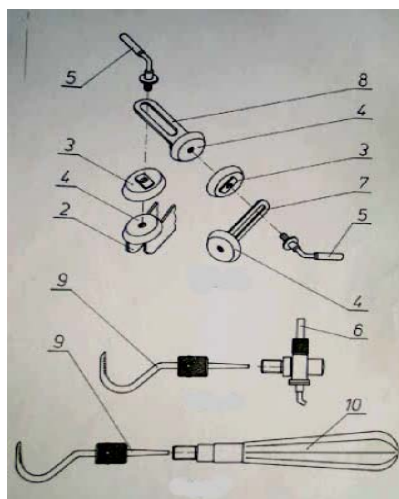


Fig. 3. Hinge construction. Single-toothed hook separated (disconnected) from the vertical arm.

## Single-toothed hook separated from a handle

The whole unit consists of a plate (1) mounting the apparatus on a plaster cap, connected to the vertical arm (6) equipped with a single-toothed hook (9), with a system of flats (7), (8). The flats (7), (8) are connected with each other by the arm (2) of the mounting plate (1) and by the vertical arm (6). Each hinge consists of the two screw-bolted, overlapping truncated cones. Internal (3) and external (4). The hinges (3), (4) of the arm (2) of the mounting plate (1) have the internal cone (4) fixed permanently to the arm (2) of the mounting plate (1). The flat (8), whose one end is permanently fixed to the internal cone (4) of the hinges (3), (4) connecting both flats (7), (8), is fixed slidably with the screw (5) to the external cone (3). The other flat (7), which is fixed permanently to the internal cone (4) of the hinges (3), (4) connecting the flat (7) with the vertical arm (6), is fixed with the screw (5) to the external cone (3) of the hinges (3), (4) connecting slidably flats (7), (8). The vertical connector (6) is fixed slidably, through the ring (12), in the external cone (3) of the hinge. The flats (7), (8) are perpendicular to each other. The position of the vertical arm (6) is fixed in the ring (12) of the external cone (3) with a set screw (11). The single-toothed hook is mounted on the vertical arm (6) separably (uncoupled).

The remaining part of the apparatus is mounted on the mounting plate on the plaster cap and one of the hooks being selected is screwed to the handle. The point of the hook insertion, i.e. point of intersection of the line parallel to the body medial line running through the lateral edge of the orbit and the horizontal line running along the lower edge of the zygoma shaft, is marked on the skin. Since the bone mass is usually dislocated dorsally or dorsally and medially, the hook should be drawn toward the front or toward the front and externally. The result of repositioning is checked visually and by palpation of the lower edge of the orbit and from the side of the oral cavity atrium on the zygomatico-orbital crest and afterwards the hook is mounted on the skeletal apparatus. The hook mounted in such a way holds the bone fragments in their anatomical position for 5–8 days.

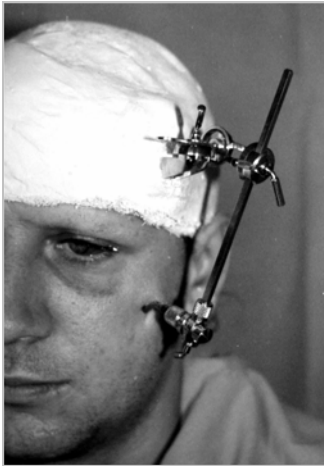

Fig. 4. Skeletal apparatus mounted on the patient head




Fig. 5. Skeletal apparatus of our own design

### 3. Results

The above-described skeletal apparatus was applied in 70 patients treated at the Clinic of Maxillofacial Surgery (Teaching Hospital) in Zabrze from March 1966 to December 2000.

The patient classification for the surgery was made after clinical and radiological examinations according to the acknowledged criteria. An experimental group consisted of 54 men, 12 women and 4 children. The patient age ranged from 13 to 50 years. The most numerous group included men at the age from 19 to 30 years. The most common causes of injuries were beatings-up (57% cases), the second common cause was traffic accidents (14%), and in the third group we dealt with falls (13%).

The reposition of the fractured bone was done not later than 2–10 days after an injury (66% cases). The remaining 34% patients were operated later than ten days after an injury. The main reason of such a delay was a faulty diagnosis made by other specialist.

Of 70 patients treated with this method and called for check-up, 39 patients responded. To standardize the evaluation criteria, the analysis of the clinical material was carried out on the basis of the questionnaire filled out by each patient.

The check-up examinations were made from 7 months to 4.5 years (3.1 years on an average) after an injury.

85% of patients declared hypaesthesia of an area innervated by infraorbital nerve directly after the injury. In most cases, the function of infraorbital nerve restored a year after the injury. However, 6% of patients complained of hypaesthesia (mainly of cheek skin) at the time of check-up.

11% of patients complained of temporary cheek pain or a pain within infraorbital area, and 7% of patients felt a temporary headache. A flattening of cheek prominence was found in 6% (4 patients) and small bone reposition at the bottom edge of an orbital cavity in 7% (5 patients). Depression of cheek skin after the hook insertion was noted in 7% of patients.

Double vision experienced by some patients ceased after hematoma and orbital tissue swelling resorption. During check-up examination, only one patient complained of double vision at the extreme, upwards position of the eye-balls. Also one patient experienced an increased lacrimation at the injury site. Within 42–55 mm there were no complications in the patients. A limited lackjaw (jaw gaping of 38 mm) was found in one patient.

Analysis of clinical material showed that the reposition of the fractured bones, which restored normal orbital cavity outlines and cheek area profile as well as enabled normal jaw gaping, was found in more than 90% of cases. Most of the positive results were achieved in treatments where surgery was performed between the second and the tenth days after injury.

In all cases, the fractured bones were stabilized with skeletal apparatus for 5–8 days.

#### **4. Discussion**

Reposition of zygomatico-orbital fractures with a single toothed hook, further mounted on a skeletal apparatus, is considered to be one of the traditional methods. Gille's method consists in bone reposition with an elevator inserted under jugular arch from the cutaneous or intraoral incision side. Bone fragments were repositioned also from the mandible sinus side or fixed with bone suture or bolts [1], [2], [15], [21].

Since the time of introducing the systems of profiled miniplates the repair of zygomatico-orbital fractures has developed into the direction of an open stable osteosynthesis [1], [3], [4], [10], [16], [20]. Recently biodegradable materials have underwent some trials [2], [5], [18]. The attempts have been made to compare various methods of treating zygomatico-orbital fractures. The best results were achieved by the authors with a stable miniplate osteosynthesis method. However, they all stressed that due to high costs of the method and the necessity, in some cases, of further removal of connecting elements and a certain number of complications, traditional methods are still valid and can be recommended [14], [15], [21].

In the cases of (one-splinter, monofragmental) zygomatico-orbital fractures, where a zygomatic bone with processes is broken out in one block, the most suitable is the reposition of bone fragments with a single-toothed hook, which is also confirmed by other authors [9], [17], [19]. The skeletal apparatus described above is small and light-weight and can be mounted in each plane, which shortens considerably the time of surgery and improves patient's comfort.

## 5. Conclusions

1. Traditional methods of zygomatico-orbital fracture treatment are still valid.
2. In the cases of monofragmental fractures, a reposition with a single toothed hook is a simple, cheap and effective procedure.
3. A construction of our skeleton apparatus allowed a decrease of its dimensions and weight and makes the mounting of a single-toothed hook easier.

## Literature

- [1] CARR R.M., MATHOG R.H., *Early and delayed repair of orbitozygomatic complex fractures*, Oral Maxillofac. Surg., 1997, 55(3), 253–258.
- [2] CHESKI P.J., MATTHIUS T.W., *Endoscopic reduction and internal cyanoacrylate fixation of the zygoma*, Otolaryngol., 1997, 26, 2, 75–79.
- [3] CHODKOWSKI G., EGGLESTON T.I., BUCHBINDER D., *Lag screw fixation of a nonstable zygomatic complex fracture*, J. Oral. Maxillofac. Surg., 1997, 55/2, 183–185.
- [4] ELLIS E., KITTIDUMKERNG W., *Analysis of treatment for isolated zygomatico-maxillary complex fractures*, Oral Maxillofac. Surg., 1996, 54/4, 386–400.
- [5] ENISLIDIS G., PIOCHORNER S., LAMBERT F. et al., *Fixation of zygomatic fractures with a new biodegradable copolymer osteosynthesis system*, Int. J. Oral. Maxillofac. Surg., 1998, 27/5, 352–355.
- [6] JANKOWSKI M., *Modyfikacja do nastawienia i ustalania złamanych kości twarzoczaszki*, Czas. Stom., 1957, IX, 8, 499–503.
- [7] JĘDRASZKO B., JUREWICZ M., *Zestaw do nastawiania i ustalania odłamów w złamaniach kości i łuku jarzmowego*, Czas. Stom., 1967, XX, 8, 843–848.
- [8] KĘPIŃSKI R., *Leczenie zespołowych złamań jarzmowo-szczękowych aparatem Jędraszki*, Czas. Stom., 1980, XXXIII, 9, 791–796.
- [9] KRYSZT L., PIEKARCZYK J., WANYURA H., SAMOLCZYK D., SZMURŁO W., SAMBORSKI K., KISŁOWSKA M., *Ocena skuteczności wybranych metod chirurgicznych w leczeniu złamań jarzmowo-szczękowych*, Czas. Stom., 1990, XLIII, 2, 73–76.
- [10] LEE C., JACOBOWICH J., MUELER R.V., *Endoscopic repair of a complex midfacial fracture*, Craniofac. Surg., 1997, 8, 13, 170–175.
- [11] ŁAZOWSKI J., KRAJNIK J., SZLĘZAK L., *Nastawianie złamanej i przemieszczonej kości i łuku jarzmowego hakiem dwuzębny własnej konstrukcji*, Czas. Stom., 1985, XXXVIII, 10, 692–695.
- [12] MARTIN R.J., GREENMAN D.N., JACKMAN D.S., *A custom splint for zygomatic fractures*, Plast. Reconstr. Surg., 1999, 103/4, 1254–1257.
- [13] MATYSZCZYK Z., *Zestaw do nastawiania i ustalania odłamów kostnych w złamaniach jarzmowo-szczękowych*, Czas. Stom., 1986, XXXIX, 9, 603–607.
- [14] O'HARA D.E. et al., *The role of microfixation in malar fractures: a quantitative biophysical study*, Plast. Reconstr. Surg., 1996, 97/2, 345–350.
- [15] O'SULLIVAN S.T., PANCHAL J., O'DONOGHUE J.M., BEAUSANG E.S., O'SHAUGHNESSY M., O'CONNOR T.P., *Is there still a role for traditional methods in the management of fractures of the zygomatic complex*, Injury, 1998, 29, 6, 413–415.
- [16] PATEL B.C., HOFFMANN J., *Management of complex orbital fractures*, Facial. Plast. Surg., 1998, 14/1, 83–104.

- [17] ROSS B., HUBERT E., GRUSZEWSKA-LEWCZUK L., BIAŁY D., *Złamania zespolone jarzmowo-szczękowe w materiale Kliniki Chirurgii Szczękowej IS AM w Białymstoku*, Czas. Stomat., 1978, XXXI, 7, 643–647.
- [18] STELNICKI E.J., HOFFMAN W.Y., OUSTECHOUD D.K., *A method for reparing zygomatic arch fractures using a hydroxyapatite cement paste*, J. Craniofac. Surg., 1997, 8/3, 236–239.
- [19] SZYSZKOWSKA A.A., GĄLKOWSKA E., *Analiza statystyczna 261 przypadków złamań zespolonych jarzmowo-szczękowych*, Czas. Stom., 1985, XXXVIII, 9, 638–643.
- [20] TOP H., ATEBAY A., BARUTCU A., *Rigid plate versus wire fixation for zygoma fractures*, Plast. Reconstr. Surg., 1996, 98/6, 1117–1118.
- [21] ZACHARIADES N., MESITIS M., ANAGNOSTOPOULOS D., *Changing trends in the treatment of zygomaticomaxillary complex fractures: a 12-year evaluation of methods used*, Oral Maxillofac. Surg., 1988, 56, 10, 1125–1126.