



Changes in muscle length and orientation after orthognathic surgeries using a bilateral sagittal split osteotomy as an example

DOMINIK PACHNICZ^{1*}, PRZEMYSŁAW STRÓŻYK², DOMINIKA GRYGIER¹

¹ Division of Automotive Engineering, Wrocław University of Science and Technology, Wrocław, Poland.

² Department of Mechanics, Materials and Biomedical Engineering,
Wrocław University of Science and Technology, Wrocław, Poland.

Purpose: The aim of the present study was to analyze the changes in the angular positions and lengths of the mandibular elevator muscles due to the displacement of bone segments after bilateral sagittal split osteotomy. Additionally, the impact of changes in mandibular geometry on the values of occlusal forces and mandibular condyle loading was considered. The combined geometric and force analysis makes a valuable contribution to the operating conditions of the system affected by the changes. *Methods:* The considerations were based on elementary principles of analytical geometry and the analysis was performed for two craniofacial geometries. *Results:* For the rotation of the proximal segment, the greatest differences in angular position concern the masseter muscle during roll rotation (11.7°). Significant changes in muscle length occurred during pitch rotation and amounted to 3.7 mm. Translation of the distal segment by 10 mm changed the angle of the pterygoid muscle by 30.2° in the coronal plane and 18.7° in the sagittal plane, simultaneously changing its direction to that of the opposite. Posterior translation (10 mm) caused an elongation of the muscle by 4.7 mm and anterior translation caused a shortening by 2.6 mm. For the mandible with elongated geometry, lower values of occlusion forces and increased reaction forces in the condyle were observed. *Conclusions:* The analysis revealed significant changes in the orientation and length of the masticatory muscles, and thus, their potential impact on the functioning conditions of the masticatory system.

Key words: mandible, geometrical analysis, muscle tension, TMJ loading

1. Introduction

One of the basic procedures affecting our appearance (face) is bilateral sagittal split osteotomy (BSSO). The main goal of this surgery is to restore the anatomically correct functionality of the masticatory system, i.e., the correction of malocclusion. During the procedure, the osteotomized bone segments, which are mainly distal, are set in a new position, in turn, providing proper bite conditions. By introducing the displacement of bone segments, the position of the muscle attachments changes, along with their length and orientation.

Studies on geometric changes and muscle orientation are often combined with the analysis of craniofacial bone morphology. There is a clear link between the above-mentioned factors regarding facial height and mandibular shape. For faces with elongated vertical dimensions, a more oblique orientation of the muscles is observed when compared to normal or short-faced subjects [24], [30]. Face types are also associated with appropriately generated bite forces: weak for dolichocephalic and strong for brachiocephalic patterns [14], [31]. The correction of craniofacial defects, which can sometimes be significant, can lead to a change in face type. The change in the length and orientation of the muscles, along with neuromuscular adaptation and

* Corresponding author: Dominik Pachnicz, Division of Automotive Engineering, Wrocław University of Science and Technology, Wrocław, ul. Ignacego Łukasiewicza 5, 50-371 Wrocław, Poland. Phone: +48 533 197 073, e-mail: dominik.pachnicz@pwr.edu.pl

Received: October 18th, 2021

Accepted for publication: December 15th, 2021

excessive soft tissue stretch, is often mentioned as one of the factors affecting the functioning of the muscular system [21], [25]. The impact of these changes, combined with an alteration of geometry, on subsequent skeletal stability can be noticed in the available literature [20], [27]. The direction of the action of muscle forces is responsible for the strain distribution in bone and cartilage, which in turn is an indicator of their growth and remodeling [3], [11]. On the other hand, stretching the muscle may cause increased loading of the mandible condyle, and consequently its remodeling. The relationship between muscle tension and skeletal relapse is indicated, among other things, by its more frequent occurrence when muscles are stretched during backward rotation of the proximal segment [15].

In a series of articles, Dicker et al. [4]–[7] investigated changes in the Masseter muscle and Medial Pterygoid muscle after the correction of mandibular hypoplasia. The results of their analysis indicate statistically significant changes in the position and geometry of muscles for the group with an increased mandibular plane angle. Along with the anterior rotation of the proximal segment, the mean value of which was 5.6° , muscle direction became by 9° more vertical. The procedure also resulted in a significant reduction in the cross-sectional area of the muscle.

The purpose of this study was the quantitative analysis of changes in the length and orientation of mandibular elevators as a result of changes in bone geometry after bilateral sagittal split osteotomy. Moreover, changes in the maximum values of occlusal forces and the values of reaction forces in the temporomandibular joint (TMJ) resulting from different muscle orientations were considered. The combined geometric and force analysis provides valuable insight into the conditions of the masticatory system. The obtained conclusions provide important information that enables geometric changes in the mandible and the functioning of the mandible's elevatory muscles, as well as the TMJ load, to be correlated.

2. Materials and methods

The elementary principles of analytical geometry were used to calculate geometric parameters (distance between the attachments and spatial orientation of muscles). The considerations were carried out for elevatory muscles: masseter (superficial and deep), temporalis (anterior, medial, posterior), and medial pterygoid. Each muscle was represented as a line passing through

the geometric centers of their attachments, which also corresponds to the line passing through the centers of the muscles' cross-sections [22]. These lines coincide with the direction of the force vector of a given muscle. Such an approximation of the muscle shape can be found in many publications. The values of changes in the muscle orientation angles were determined in three main planes. The reference planes and directions of measurements are shown in Fig. 1. The length of the muscle is the distance between the points defining the geometric centers of the muscles' attachment and origin.

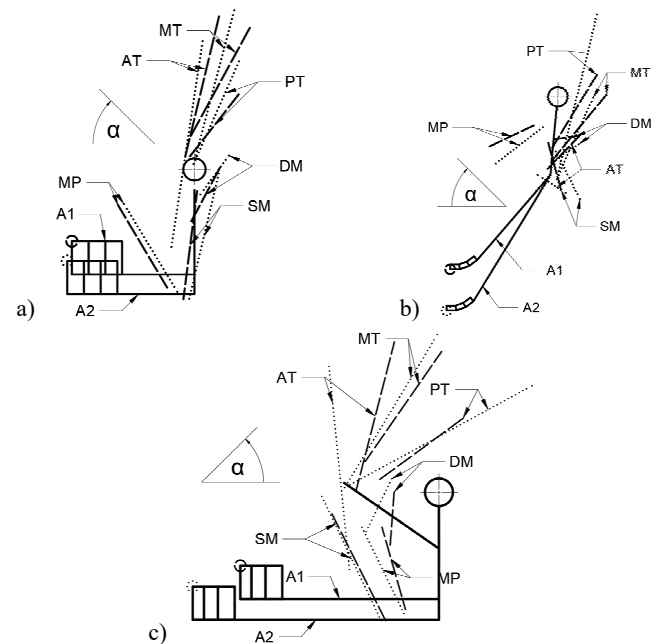


Fig. 1. Orientation of the masticatory muscles (dashed-A1 model, dotted-A2 model): a) frontal, b) coronal, c) sagittal plane

The analysis was performed for given bone segment displacements:

- rotation of the proximal segment in three directions (yaw, roll, pitch) relative to the center of the coordinate system located at the condylar process O (0, 0, 0),
- translation of the distal segment in the sagittal axis.

The range of proximal segment rotation (from -5 to 5°) and distal segment translation (from -10 to 10 mm) was based on the literature [18], [26], [29]. The assumed ranges correspond to permanent displacements after full body union. The data of the coordinates of the muscle attachments were determined for two models: the first (A1) – the author's geometry was built on an anatomically correct polyurethane model of the human mandible (Synbone 8596) and skull (Synbone 8500); the second (A2) – was described in the work of Nel-

Table 1. Coordinates of muscle attachments and origins

Model A1						
	Origin			Attachment		
	<i>x</i>	<i>y</i>	<i>z</i>	<i>x</i>	<i>y</i>	<i>z</i>
SM	38.3	1.3	-7.9	18.9	-3.8	-46.7
DM	15.9	9.4	0.3	17.5	-1.0	-19.2
PL	20.4	-27.5	-12.7	11.9	-9.6	-42.7
TA	16.0	9.0	55.0	29.7	-4.1	0.6
TM	-1.0	20.0	51.0	26.3	-2.3	11.4
TP	-9.0	16.0	27.0	21.1	-1.3	4.7
Model A2						
	Origin			Attachment		
	<i>x</i>	<i>y</i>	<i>z</i>	<i>x</i>	<i>y</i>	<i>z</i>
SM	41.9	8.9	-1.6	20.6	-1.7	-46.6
DM	16.8	12.5	5.0	26.0	1.6	-14.5
PL	27.5	-25.3	-12.7	12.6	-6.0	-44.2
TA	39.4	3.1	45.8	32.1	-8.1	-28.0
TM	0.5	14.4	57.4	33.8	-0.4	1.6
TP	-33.7	16.1	38.7	33.6	-0.3	1.4

Table 2. Initial muscle orientation [°]

	A1			A2		
	Sagittal	Coronal	Frontal	Sagittal	Coronal	Frontal
SM	116.57	165.25	97.50	115.34	153.70	103.17
DM	85.29	81.25	118.19	64.63	49.56	119.10
MP	105.92	205.60	59.25	115.37	217.68	58.45
TA	75.86	43.83	103.60	95.65	123.21	98.59
TM	55.39	39.22	119.39	59.16	23.93	104.84
TP	36.49	29.88	127.83	29.01	13.69	113.72

son [17]. The coordinates of the attachments and the initial values of the angles for both systems are presented in Tables 1 and 2.

The effect of changes in muscle orientation on the biomechanics of the masticatory system was analyzed in terms of static equilibrium. Same, constant value of force for each muscle was assumed for the system before and after geometric changes. Loading conditions for intercuspal clenching were recreated based on [17]. The analysis was performed for the planar force system in the sagittal plane. The comparison was based on the value of the resulting force on the incisors and the reaction forces in the mandibular condyle.

3. Results

In the available literature, there is a lack of quantitative analysis that focuses on changes in the angular position of the masticatory muscles after orthognathic surgery. According to the authors' knowledge, the only

study of this kind was carried out by Dicker et al. [6]. On the basis of this study, 2.8° was assumed as the significant value of the angular change, which corresponded to statistical significance at the level of 0.05. In Table 2, the changes in angular position for individual muscles are summarized.

With any rotation of the proximal segment, significant changes can be seen in the case of the masseter muscle. They also occurred in the coronal plane, where the greatest difference in position was observed for the superficial masseter during roll rotation. It was 11.7° for A1 and 9.4° for A2 geometry, respectively. Significant changes in the angle in the sagittal plane occurred only during pitch rotation and only in the masseter muscle – mostly in the deep layer of the muscle. Yaw rotation has the main impact on the position of the temporal muscle. It was only for the A2 model that changes were noticed in the coronal plane with other rotations. With translation of the distal segment, the position of the medial pterygoid muscle can change by up to 18.6° in the sagittal plane and by 30.2° in the coronal plane. In addition, the direc-

tion of the muscle in the sagittal plane changed to the opposite when the distal segment was advanced more than 8 mm. From an acute angle in the sagittal plane, it changes to an obtuse angle in the sagittal plane. The muscle, therefore, takes a non-anatomical direction of action (Fig. 2).

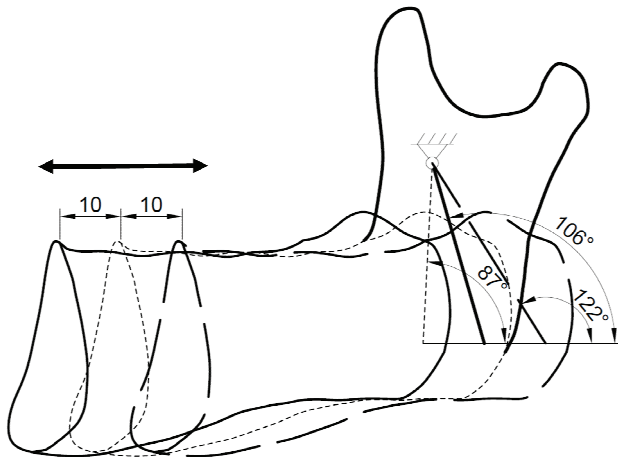


Fig. 2. Changes in medial pterygoid muscle orientation after distal segment advancement

In Table 3, the values of muscle length changes are shown. The results are only summarized for elongation/shortening of more than 1 mm. This value was adopted on the basis of the work by Grunheid et al. [9]. For proximal segment rotations, significant changes in length only occur during pitch rotation. The greatest differences were observed for the superficial masseter and anterior temporalis muscle. For extreme values of proximal segment displacement, the change in length can increase by 3.7 mm, which is almost 8% of the initial length of the masseter muscle. Posterior translation of the distal segment affects changes in the length of the medial pterygoid muscle more than anterior translation. The maximum values of elongation were 3.5 mm and 4.7 mm for A1 and A2, respectively. During mandibular advancement, the muscle length decreased by 1.2 mm (A1) and 2.6 mm (A2).

In the analysis of alterations in biomechanics, a constant total force generated by each muscle was assumed for all the considered displacements. The values were adopted from the literature [17]. For the basic models without geometrical changes, the occlusal force was 282 N (A1) and 261 N (A2). The translation of the

Table 3. Muscle angular changes A1

°	Pitch				Roll			Yaw					mm	Translation	
	Sagittal		Coronal		Coronal	Frontal		Coronal			Frontal			Sagittal	Coronal
	SM	DM	SM	DM	SM	SM	DM	SM	TA	TM	DM	TP		MP	
-5	-3.94	-5.48	-3.59	-8.37	-10.52	5.95	3.90	-4.05	6.10	3.08	3.38	2.83	-10	15.81	20.49
-4	-3.14	-4.35	-	-6.80	-8.54	4.76	3.12	-3.29	4.93	-	-	-	-8	12.96	17.22
-3	-	-3.24	-	-5.18	-6.50	3.58	-	-	3.73	-	-	-	-6	9.95	13.57
-2	-	-	-	-3.50	-4.39	-	-	-	-	-	-	-	-4	6.79	9.50
-1	-	-	-	-	-	-	-	-	-	-	-	-	-2	3.46	4.98
1	-	-	-	-	-	-	-	-	-	-	-	-	2	-3.59	-5.44
2	-	-	-	3.69	4.59	-	-	-	-	-	-	-	4	-7.27	-11.28
3	-	3.09	-	5.59	6.94	-3.59	-	-	-	-	-	-	6	-11.04	-17.44
4	3.01	4.10	-	7.53	9.32	-4.79	-3.18	3.61	-5.33	-	-2.88	-	8	-14.84	-23.80
5	3.74	5.09	2.51	9.49	11.72	-5.99	-3.99	4.55	-6.74	-3.12	-3.62	-3.08	10	-18.65	-30.20

Table 4. Muscle angular changes A2

°	Pitch						Roll				Yaw							mm	Translation	
	Sagittal		Coronal			Frontal	Coronal			Frontal	Coronal				Frontal				Sagittal	Coronal
	SM	DM	SM	DM	TA	DM	SM	DM	TA	SM	SM	DM	TA	TM	DM	TM	TP		MP	
-5	-3.41	-5.87	-5.00	-3.39	-9.12	3.20	-8.10	3.10	-4.91	4.91	-3.48	5.16	-2.94	4.21	4.86	-	3.66	-10	13.01	14.53
-4	-	-4.65	-3.88	-	-7.25	-	-6.59	-	-4.05	3.94	-2.82	4.18	-	3.38	3.93	-	2.95	-8	10.70	12.19
-3	-	-3.46	-2.83	-	-5.40	-	-5.03	-	-3.13	2.96	-	3.17	-	-	2.98	-	-	-6	8.25	9.60
-2	-	-	-	-	-3.57	-	-3.41	-	-	-	-	-	-	-	-	-	-	-4	5.65	6.72
-1	-	-	-	-	-	-	-	-	-	-	-	-	-	-	-	-	-	-2	2.90	3.53
1	-	-	-	-	-	-	-	-	-	-	-	-	-	-	-	-	-	2	-3.04	-3.90
2	-	-	-	-	3.43	-	3.62	-	-	-	-	-	-	-	-	-	-	4	-6.23	-8.20
3	-	3.30	-	-	5.09	-	5.51	-	3.82	-2.99	-	-3.45	2.99	-	-3.15	-	-	6	-9.54	-12.89
4	-	4.37	3.13	3.46	6.70	-	7.45	3.61	-5.33	-3.99	3.13	-4.67	4.27	-3.45	-4.23	-	-3.09	8	-12.96	-17.96
5	3.29	5.43	3.82	4.45	8.27	-	9.43	4.55	-6.74	-5.00	3.96	-5.94	5.72	-4.33	-5.34	-2.87	-3.88	10	-16.48	-23.38

distal segment affects the length of the moment arm of the occlusal force, which in turn has a significant impact on the value of the force. During mandibular setback by 10 mm, occlusion forces increased by 48 N and 32 N, respectively for geometries A1 and A2. For the same range of advancement, it decreased by 33 N and 28 N. Pitch rotation of the proximal segment resulted in changes ranging from 7 N to almost 10 N.

In Figure 2, the values of the reaction force components in the mandibular condyle in the sagittal (*X*) and vertical (*Z*) axes are shown. Upward rotation of the proximal segment caused an increase in both reaction components. For the maximum values of rotation, these changes were 7 N in the *Z*-axis and 23 N in the *X*-axis for model A1, and respectively 12 N and 25 N

for model A2. Moreover, with a more anterior position of the distal segment, the value of the *X*-component decreased and the value of the *Z*-component increased. The force changes reached their maximum values of 42 N and 68 N in the *X* and *Z* axes, respectively.

4. Discussion

The topic of the relationship between the morphology of craniofacial bones and the functioning of the muscle system has been extensively studied and highlighted in the literature for decades [7]. Such relations are noticed for muscle orientation, anatomical

Table 5. Muscle length changes [mm] (percentage value of change)

A1							
	SM	DM	TA	TM	TP		MP
-5	-3.7 (-7.6)	-1.4 (-5.6)	-2.9 (-4.8)	-2.1 (-4.9)	-1.5 (-3.2)	-10	3.5 (8.6)
-4	-3 (-6.1)	-1.1 (-4.5)	-2.3 (-3.8)	-1.7 (-3.9)	-1.2 (-2.6)	-8	2.6 (6.5)
-3	-2.2 (-4.6)	-	-1.7 (-2.9)	-1.3 (-3)	-	-6	1.8 (4.5)
-2	-1.5 (-3)	-	-1.1 (-1.9)	-	-	-4	1.1 (2.8)
2	1.5 (3)	-	1.1 (1.9)	-	-	4	-
3	2.2 (4.5)	-	1.7 (2.9)	1.3 (3)	-	6	-1 (-2.5)
4	2.9 (6)	1.1 (4.6)	2.3 (3.8)	1.7 (4)	1.2 (2.5)	8	-1.1 (-2.8)
5	3.7 (7.5)	1.4 (5.7)	2.8 (4.8)	2.2 (5)	1.5 (3.1)	10	-1.2 (-2.9)
A2							
	SM	DM	TA	TM	TP		MP
-5	-3.3 (-6.5)	-1.3 (-5.5)	-3.1 (-4.1)	-2.6 (-3.9)	-1.6 (-2)	-10	4.7 (11.9)
-4	-2.7 (-5.2)	-1.1 (-4.4)	-2.4 (-3.2)	-2.1 (-3.1)	-1.2 (-1.6)	-8	3.6 (9.1)
-3	-2 (-3.9)	-	-1.8 (-2.4)	-1.5 (-2.3)	-	-6	2.6 (6.6)
-2	-1.3 (-2.6)	-	-1.2 (-1.6)	-1 (-1.5)	-	-4	1.7 (4.2)
2	1.3 (2.6)	-	1.2 (1.6)	1 (1.5)	-	4	-1.3 (-3.3)
3	2 (3.9)	-	1.8 (2.4)	1.5 (2.3)	-	6	-1.8 (-4.6)
4	2.6 (5.1)	1.1 (4.5)	2.4 (3.1)	2 (3)	1.2 (1.5)	8	-2.3 (-5.7)
5	3.3 (6.4)	1.4 (5.7)	2.9 (3.9)	2.5 (3.7)	1.4 (1.8)	10	-2.6 (-6.5)

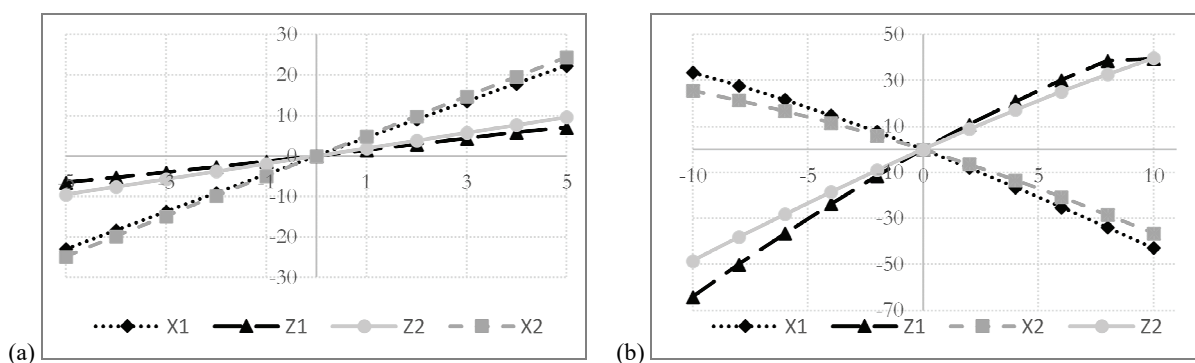


Fig. 3. Components of the reaction force in mandibular condyle [N]: (a) proximal segment pitch rotation, (b) distal segment translation

characteristics, neuromuscular activity, and forces generated in the system. Skeletal corrections introduced during orthognathic surgery cause changes in both soft tissues and the positions of muscle attachments, and, in turn, the orientation, shortening or elongation of muscles. Changing one of the factors will, therefore, affect the others, thereby, inducing an adaptive response in the postoperative period [1], [9], [12], [20]. A summary of information from research on the adaptation of the craniofacial muscles can be found in the paper by Grunheid et al. [9].

One of the factors initiating changes in the structure and functioning of muscles is tension. Significant stretch-induced hypertrophy may occur in stretched muscles, i.e., digastic muscles during mandibular advancement or masseter and medial pterygoid muscles during mandibular setback [2]. Elongation alters the composition of the muscle fibers towards a higher percentage of slow fibers, while at the same time increasing the muscles's length by producing more sarcomeres [8]. Grunheid et al. [9] also mention the golden rule that the pterygo-masseteric sling must not be stretched, otherwise skeletal relapse is likely to occur. Therefore, the question arises whether the range of acceptable stretching of the craniofacial muscles can be indicated? The most commonly considered muscles in this context are the digastic muscles that undergo extension during mandibular advancement and distraction. It is assumed that the safe range of distraction that provides adequate conditions for bone and muscle tissue remodeling is 1 mm per day [28]. Exceeding this may lead to contractile material damage by overstretching and further insufficient regeneration. It should be mentioned that the value of digastic muscle elongation is smaller than the range of distraction. This may, therefore, indicate that a safe amount of muscle stretch is less than one millimeter per day. Mackool et al. [16] noticed that the advantage of distraction over traditional mandibular advancement is the gradual introduction of the displacement, which allows the soft tissues to adapt appropriately. Considering the above and the obtained results, it can be concluded that the displacement of the bone segments during orthognathic surgeries (i.e., pitch rotation, posterior translation) may lead to temporary, excessive muscle traction. It is worth mentioning that shortened muscles, e.g., medial pterygoid during anterior translation of the distal segment, become understretched and undergo a similar remodeling process. In both cases, passive stiffness may occur [32]. The results of changes in muscle length presented in the paper refer to permanent displacement of bone segments (after full mandibular bone union). It should be kept in mind that these val-

ues are often much smaller than surgical changes. The bone segment displacements introduced during the surgery are reduced during the period of bone healing and remodeling [18]. There is a tendency of the system to return to its original position, which is related, among others, to the tension in soft tissues and muscles.

A subject often discussed in many publications is the stability of treatment results, which is often measured by skeletal relapse. Correlations are sometimes sought in the changes in the biomechanics of the masticatory system. The muscles directly act on the skeletal system through attachments, the position of which changes during surgery. This is also the case with muscle orientation, and, therefore, the direction of the force action. The distribution of forces in the masticatory system is to be altered, including both the muscle forces and the reaction forces in the temporomandibular joints. A statement on this issue is presented by Hwang et al. [13]. The authors note that new biomechanical conditions may contribute to changes in bone geometry in the postoperative period, which are largely related to bone remodeling. The opposite view is taken by Dicker et al. [6]. They do not support the hypothesis that postoperative changes, e.g., mandible condyle resorption or increased occlusal force, result from improved biomechanical conditions [4], [10]. Despite statistically significant changes in the orientation of the masseter and medial pterygoid muscles during mandibular advancement, changes in biomechanical conditions should not cause the remodeling of bony structures. Their analysis showed only a slight increase in the maximum reaction force on the condyle. A more vertical orientation of the muscles may contribute to their more efficient action and an increased vertical component of the muscle force. Another point the authors mention is the reduction of the muscle's cross-sectional area, which is supposed to cause the capability of the muscle to generate force in order to decrease. This conclusion is consistent with the statement that the maximum force of a muscle is dependent on its cross-sectional area. The analysis of the muscle forces in the masticatory system under static load conditions admittedly showed slight changes in their values, which resulted from pitch rotation of the proximal segment. However, as the distal segment is advanced, the forces increase significantly [19].

The results of the mechanical analysis presented here indicate that the position of the distal segment has a significant effect on the value of the occlusal force. The loading conditions of the condyle also change. From a mechanical point of view, the obtained results seem to favor the first hypothesis [13]. With mandible

setback of 10 mm, the occlusal force increased by 17%, while for advancement of 10 mm it decreased by 11%, compared to the preoperative value. The reaction forces of joints simultaneously decreased by 20% and increased by 15% for posterior and anterior translation of the distal segment, respectively. With the rotation of the proximal segment, the change in the value of the occlusion force did not exceed 4%. The reaction force in the joint increased by up to 7%. The altered loading conditions of the condylar head may lead to remodeling due to changes in strain distribution. Both excessive and reduced loading may lead to resorption and bone loss [11]. It should be mentioned that soft tissues, including muscles, characterizes with elasticity and stiffness. In the initial postoperative period additional forces resulting from tissue tension is present in the system. These forces may alter the loading conditions of the temporomandibular joint. The presented analysis does not take into account the given forces due to the consideration of conditions after complete bone union. After a given period of time, it can be assumed that the given loads have no effect due to the initial adaptation of the system.

The obtained changes in the values of occlusion forces are consistent with the data presented in clinical reports. For subjects with elongated facial dimensions, lower values of occlusion forces are observed than for short facial morphology [14], [31]. As the length of the mandibular body increases, the moment arm of the occlusal force simultaneously increases. This results in greater masticatory muscle activity or a decreased occlusal force value and, in both cases, an increased reaction force at the temporomandibular joint. With the advancement of the distal segment, the pterygoid muscle becomes more vertical, which results in an increase in the vertical component of the force and a decrease in the horizontal component. Anterior rotation of the proximal segment similarly results in a more vertical orientation of the masseter, thus also causing a possible increase in the occlusal force. To a lesser extent, however, it affects the position of the temporalis muscle, which becomes oriented slightly more horizontally, thereby, increasing the reaction force component in that direction. However, the origin of the temporal muscle is so extensive that such minor angular changes may not actually have a significant effect on its function.

In the presented analysis, muscles were represented as a single line. Reducing the muscle force to a single vector is a considerable simplification. However, it does allow for changes in the magnitude of the force components in individual directions to be con-

sidered. Although justified, this does not fully reflect the much more complex real conditions. The muscle, in its volume, is made up of numerous fibers running between its attachment and origin. The masticatory muscle attachments are distributed over a large area of the bone. Surgical changes can, therefore, affect the stretching of the fibers to a different extent, depending on what part of the muscle they are located on. As a result of backward pitch rotation, the anterior part of the superficial masseter might be stretched more than the posterior part. Moreover, masticatory muscles have a relatively large surface area of attachments when compared to the length and volume of the muscle. In fact, the distribution of forces across the surface is not uniform. Similarly, the vector of forces generated by the muscle does not coincide with the direction of its linear representation [23].

The analysis of anatomically correct craniofacial models can also be seen as a limitation of the given study. Such morphology can be seen to be different than the actual anatomy, with defects occurring in the positions of muscle attachments, the initial orientation of muscles, the length of the mandibular ramus and the length of the mandible itself. As a result, the analyzed values for the assumed displacements will differ. However, they should be significantly different, which can be seen by the similarity of the results obtained for both geometries.

The performed quantitative analysis concerns single changes in the geometry of the mandible. Such considerations are difficult to generalize and translate into real cases with complex geometry changes. There are no visible patterns concerning the displacements of fragments and the relationship between changes in geometry and specific treatments [18]. A full analysis requires the consideration of combinations of these displacements, which can be infinite in number. An accurate reference to real conditions is an additional complex issue due to, among other things, the small number of clinical reports that present quantitative data. Similar to the conclusions in Dicker et al. [5], the clinical significance of the presented results for muscle angular positions is still to be determined. They show the extent to which particular displacements of bone segments will affect the change in the geometry of the muscular system, and thus, the load conditions. In addition, a significant impact of changes in bone morphology introduced during the procedures on the length of the muscles and the biomechanics of the masticatory system was noticed. Modern techniques of planning surgery allow the positions of bone segments to be predicted. The presented results,

taking the necessity of additional operations such as muscle detachment into account, may, therefore, be useful.

5. Conclusions

The presented analysis provides a biomechanical perspective on the issue of changes in the orientation and length of the masticatory muscles, as well as their influence on mandibular loading conditions. The changes introduced during orthognathic procedures significantly affect the considered issues, which may constitute an important factor for the remodeling of the musculoskeletal system. Based on the analysis of the results, the following conclusions were drawn:

- Translation of the distal segment significantly affects the position of the medial pterygoid muscle. With the mandibular setback, the muscle direction can even be by 23° more horizontal. With large ranges of the mandible protrusion, the direction of the muscle's action may change to the opposite – the non-anatomical one,
- Pitch rotation of the proximal segment, and translation of the distal segment may cause excessive stretching of the masticatory muscles, as well as changes in the value and direction of the reaction force in the mandibular condyle,
- Changes in the value of the occlusal force are mainly affected by the translation of the distal segment in the sagittal plane.

Acknowledgements

We thank Professor António Ramos for useful suggestions and comments on the manuscript.

References

- [1] AN S., PARK S., KIM Y., SON W., *Effect of post – orthognathic surgery condylar axis changes on condylar morphology as determined by 3-dimensional surface reconstruction*, Angle Orthod., 2014, 84 (2), 316–321.
- [2] CARLSON D.S., ELLIS E., DECHOW P.C., NEMETH P.A., *Short-term stability and muscle adaptation after mandibular advancement surgery with and without suprahyoid myotomy in juvenile Macaca mulatta*, Oral Surg. Oral Med. Oral Pathol., 1989, 68 (2), 135–149.
- [3] CARTER D.R., WONG M., ORR T.E., *Musculoskeletal ontogeny, phylogeny, and functional adaptation*, J. Biomech., 1991, 24 (1), 3–16.
- [4] DICKER G.J., CASTELIJNS J.A., TUINZING D.B., STOELINGA P.J.W., *Do the changes in muscle mass, muscle direction, and rotations of the condyles that occur after sagittal split advancement osteotomies play a role in the aetiology of progressive condylar resorption?*, Int. J. Oral Maxillofac. Surg., 2015, 44 (5), 627–631.
- [5] DICKER G.J., KOOLSTRA J.H., CASTELIJNS J.A., VAN SCHIJNDEL R.A., TUINZING D.B., *Positional changes of the masseter and medial pterygoid muscles after surgical mandibular advancement procedures: an MRI study*, Int. J. Oral Maxillofac. Surg., 2012, 41 (8), 922–929.
- [6] DICKER G.J., TUIJT M., KOOLSTRA J.H., VAN SCHIJNDEL R.A., CASTELIJNS J.A., TUINZING D.B., *Static and dynamic loading of mandibular condyles and their positional changes after bilateral sagittal split advancement osteotomies*, Int. J. Oral Maxillofac. Surg., 2012, 41 (9), 1131–1136.
- [7] DICKER G.J., VAN SPRONSEN P., VAN SCHIJNDEL R. et al., *Adaptation of jaw closing muscles after surgical mandibular advancement procedures in different vertical craniofacial types: a magnetic resonance imaging study*, Oral Surg. Oral Med. Oral Pathol. Oral Radiol. Endod., 2007, 103 (4), 475–482.
- [8] GOLDSPIK G., *Cellular and molecular aspects of muscle growth, adaptation and ageing*, Gerodontology, 1998, 15 (1), 35–43.
- [9] GRUNHEID T., LANGENBACH G.E.J., KORFAGE J.A.M., ZENTNER A., VAN EIJDEN T.M.G.J., *The adaptive response of jaw muscles to varying functional demands*, Eur. J. Orthod., 2009, 31 (6), 596–612.
- [10] HA M.H., KIM Y.I., PARK S.B., KIM S.S., SON W.S., *Cone-beam computed tomographic evaluation of the condylar remodeling occurring after mandibular set-back by bilateral sagittal split ramus osteotomy and rigid fixation*, Korean J. Orthod., 2013, 43 (6), 263–270.
- [11] HERRING S.W., *Masticatory muscles and the skull: A comparative perspective*, Arch. Oral Biol., 52 (4), 296–299.
- [12] HOPPENREIS T., MAAL T., XI T., KONING M. DE, BERG S., *The role of mandibular proximal segment rotations on skeletal relapse and condylar remodelling following bilateral sagittal split advancement osteotomies*, Craniomaxillofac. Surg., 2015, 43 (9), 1716–1722.
- [13] HWANG S.J., HAERS P.E., ZIMMERMANN A., OECHSLIN C., SEIFERT B., SAILER H.F., *Surgical risk factors for condylar resorption after orthognathic surgery*, Oral Surg. Oral Med. Oral Pathol. Oral Radiol. Endod., 2000, 89 (5), 542–552.
- [14] INGERVALL B., THILANDER B., *Relation between facial morphology and activity of the masticatory muscles*, J. Oral Rehabil., 1974, 1 (2), 131–147.
- [15] JOSS C.U., VASSALLI I.M., *Stability After Bilateral Sagittal Split Osteotomy Advancement Surgery With Rigid Internal Fixation: A Systematic Review*, J. Oral Maxillofac. Surg., 67 (2), 301–313.
- [16] MACKOOL R.J., HOPPER R.A., GRAYSON B.H., HOLLIDAY R., MCCARTHY J.G., *Volumetric change of the medial pterygoid following distraction osteogenesis of the mandible: An example of the associated soft-tissue changes*, Plast. Reconstr. Surg., 2003, 111 (6), 1804–1807.
- [17] NELSON G.J., *Three dimensional computer modeling of human mandibular biomechanics*, Dissertation, The University of British Columbia, 1986.
- [18] PACHNICZ D., RAMOS A., *Mandibular condyle displacements after orthognathic surgery – an overview of quantitative studies*, Quant. Imaging Med. Surg., 2021, 11 (4), 1628–1650.

- [19] PACHNICZ D., STRÓZYK P., *A Biomechanical Analysis of Muscle Force Changes After Bilateral Sagittal Split Osteotomy*, *Front Physiol.*, 2021, 12, 679644, DOI: 10.3389/fphys.2021.679644.
- [20] PARK S.B., YANG Y.M., KIM Y. IL, CHO B.H., JUNG Y.H., HWANG D.S., *Effect of bimaxillary surgery on adaptive condylar head remodeling: Metric analysis and image interpretation using cone-beam computed tomography volume superimposition*, *J. Oral Maxillofac. Surg.*, 2012, 70 (8), 1951–1959.
- [21] PROFFIT W.R., TURVEY T.A., PHILLIPS C., *Orthognathic surgery: a hierarchy of stability*, *Int. J. Adult Orthodon. Orthognath. Surg.*, 1996, 11 (3), 191–204.
- [22] PRUIM G.J., DE JONGH H.J., TEN BOSCH J.J., *Forces acting on the mandible during bilateral static bite at different bite force levels*, *J. Biomech.*, 1980, 13 (9), 755–763.
- [23] RÖHRLE O., PULLAN A.J., *Three-dimensional finite element modelling of muscle forces during mastication*, *J. Biomech.*, 2007, 40 (15), 3363–3372.
- [24] SELLA-TUNIS T., POKHOJAEV A., SARIG R., O’HIGGINS P., MAY H., *Human mandibular shape is associated with masticatory muscle force*, *Sci. Rep.*, 2018, 8 (1), 1–10.
- [25] TAKADA K., LOWE A.A., FREUND V.K., *Canonical correlations between masticatory muscle orientation and dentoskeletal morphology in children*, *Am. J. Orthod.*, 1984, 86 (4), 331–341.
- [26] THROCKMORTON G.S., JOHNSTON C.P., GONYEA W.J., BELL W.H., *A preliminary study of biomechanical changes produced by orthognathic surgery*, *J. Prosthet. Dent.*, 1984, 51 (2), 252–261.
- [27] VAN DEN BEMPT M., VINAYAHALINGAM S., HAN M.D., BERGÉ S.J., XI T., *The role of muscular traction in the occurrence of skeletal relapse after advancement bilateral sagittal split osteotomy (BSSO): A systematic review*, *Orthod. Craniofacial. Res.*, 2021, DOI: 10.1111/OCR.12488.
- [28] VAN DER MEULEN J.H., BORSCHEL G.H., LYNCH J.B. et al., *The effect of rate of distraction osteogenesis on structure and function of anterior digastric muscle fibers*, *Plast. Reconstr. Surg.*, 2005, 115 (3), 831–837.
- [29] VAN SICKELS J.E., HATCH J.P., DOLCE C., BAYS R.A., RUGH J.D., *Effects of age, amount of advancement, and genioplasty on neurosensory disturbance after a bilateral sagittal split osteotomy*, *J. Oral Maxillofac. Surg.*, 2002, 60 (9), 1012–1017
- [30] VAN SPRONSEN P.H., KOOLSTRA J.H., VAN GINKEL F.C., WEIJS W.A., VALK J., PRAHL-ANDERSEN B., *Relationships between the orientation and moment arms of the human jaw muscles and normal craniofacial morphology*, *Eur. J. Orthod.*, 1997, 19 (3), 313–328. DOI: 10.1093/ejo/19.3.313.
- [31] VAN SPRONSEN P.H., WEIJS W.A., VALK J., PRAHL-ANDERSEN B., VAN GINKEL F.C., *A Comparison of Jaw Muscle Cross-sections of Long-face and Normal Adults*, *J. Dent. Res.*, 1992, 71 (6), 1279–1285.