

Magnetic resonance imaging (MRI) for assessment of differences in geometrical parameters in muscles stabilizing vertebral column in young and older persons. Case study

ALICJA DZIUBA^{1*}, ALICJA RUTKOWSKA-KUCHARSKA¹, ANDRZEJ HADZIK²,
MAREK RUDZIŃSKI¹, JERZY GARCAREK³

¹ Institute of Biomechanics, University School of Physical Education in Wrocław.

² NZOZ Konsylium, a partnership, ul. Siemieńskiego 4a/1a, Wrocław.

³ Department of Radiology, The Piastów Śląskich Medical University, Wrocław.

Today non-traumatic low back pain (LBP) is a social disease being attributed to weakening the function of abdominal and back muscles. Condition of deep muscles, inaccessible to non-invasive examinations, can be assessed by means of magnetic resonance imaging (MRI). The method allows for the assessment of cross-sections, muscle girths, as well as their intensity (brightness). The aim of the investigations was to determine the opportunities to employ MRI technique for assessing the geometry of muscles which stabilize spinal column. The study covered 4 women without LBP symptoms. The cross-sectional area, thickness and brightness of abdominal and back muscles were measured at the level of L3–L4. Measurement of geometrical parameters in the positions studied was aimed at setting such measurement conditions that would force higher isometric contraction in the muscles examined. As a result of measurements it can be inferred that other conditions of the experiment affect neither an increase in cross-sectional surface area nor the thickness of the muscles examined. The differences observed in geometrical parameters of the muscles testify to different coordination of muscle activation in the positions studied, both in young and older subjects, and to the purposefulness of continuing this type of measurements.

Key words: MRI, low back pain, muscle geometry, trunk muscles

1. Introduction

One of the main diseases today, referred to as social diseases, being attributed to civilization development, is non-traumatic low back pain (LBP). The incidence of such a disorder increases with age: in population of adults, it accounts for 20%, and in persons older than 65, it might even rise up to 49% [1]. This frequent incidence of pain in this body part is caused by upright body position, adopted throughout human evolution, without sufficiently prepared lumbosacral part of spinal column. It is claimed that one

of the main causes for LBP is the weakening of abdominal and trunk muscles [2], which are the major stabilizers for spinal column and maintain its natural curvatures. A fundamental problem in the occurrence of pain in human back is non-physiological body posture in sitting position. Moreover, limited physical activity of humans leads to the weakening of the muscles which stabilize spinal column, and, as a consequence, to the overload in this area.

According to TYLMAN [3] physiological shape of spinal column remains unchanged if the abdominal and back muscles are maintained in the condition of symmetric muscle tone. There is a direct relationship

* Corresponding author: Alicja Dziuba, Institute of Biomechanics, University School of Physical Education in Wrocław, al. Paderewskiego 35, 51-612 Wrocław. Phone +48 601404654, e-mail: alicja.dziuba@awf.wroc.pl

Received: May 18th, 2010

Accepted for publication: August 27th, 2010

between the state of active muscle tone and curvature of spinal column: if the state of muscle tone is changed, spinal curvatures are changed, and vice versa, each change in spinal curvature entails changes in muscle tone.

The muscles responsible for the stabilization and movements of the vertebral column are characterized by the largest physiological cross-sectional surface area, thus they are the strongest group in relation to the muscles in thoracic and cervical parts. Frontal muscles in the trunk, i.e. abdominal muscles, although not directly adjacent to vertebral column, constitute, together with diaphragm, the abdominal prelum which stabilizes vertebral column.

An assessment of the condition of the muscles which fulfil the function of primary stabilizers [4] or the effect of their strengthening through regular exercising is possible only through the application of harmless (to human health) magnetic resonance imaging (MRI) [5]. The benefits from the application of this method include a perfect, contrasting view of soft tissues, the arbitrariness of selecting the plane studied, the minimization of artefacts from bones and gases, the opportunity to measure flow of blood and other body fluids. MRI method allows for fast and non-invasive evaluation of cross-sections of the muscles and thus of specific muscle strength [6] and fat content in the muscles [7]. Therefore, it is becoming increasingly popular for the assessment of active motor system.

GZIK et al. [8] used MRI for determining mechanical parameters necessary for modelling a cervical part of human vertebral column. They determined the kinematics of cervical vertebrae during head movements in sagittal and frontal planes, the mechanical properties of cervical part and the stiffness of ligaments and intervertebral discs. HIDES et al. [9] compared two methods of imaging the measurement for the multifidus (MF) m. in 10 women aged 21–31. MRI imaging was carried out on the first day, whereas on the second day USG examination was performed. Bilateral measurements were taken at each level of vertebrae L2–S1. No significant differences in cross-sectional areas were revealed between MRI and USG images. Cross-sections in multifidus (MF) m. showed symmetry in both sides of vertebral column.

MOONEY et al. [10] studied the effect of 8-week training on cross-sectional area of muscles by means of MRI and electrical activity in muscles (EMG) among patients with LBP. They reported rise in EMG activity in muscles and reduced pain in patients with chronic pain in lumbar area of the vertebral column. Moreover, a reduced amount of fat content was ob-

served in the muscles examined after training, especially in psoas major (PS) m.

WOOD et al. [7] recorded magnetic resonance images for back and abdominal muscles at the level of L4–L5 in 26 slim and obese males (BMI ranged from 19.7 to 39.5). Cross-sectional areas of muscles did not differ between slim and obese persons. However, normalized parameters showed statistically significant differences. The study showed larger relative cross-sectional areas in the muscles examined in slim persons.

MARRAS et al. [11], using MRI methods, developed the characteristics of cross-sectional areas (CSA) in trunk muscles in males and females at different levels of thoracic and lumbar parts of the vertebral column. They searched for formulas for forecasting physiological cross-sectional areas, depending on gender and anthropometrical data. Significant differences, depending on gender, were observed in cross-sectional areas of the following muscles: erector spinae (ES) m., internal and external obliques (OAI, OAE) mm., psoas major (PS) m. and quadratus lumborum (QL) m. The coefficients of cross-sectional areas, depending on body height and mass, gave better prognoses for muscle cross-sections compared to traditional anthropometrical measurement.

HIDES et al. [12] employed MRI for investigating the area, symmetry and functions of trunk muscles in cricket players. Cross-sectional areas, at the level L3–L4 in time T_2 , of rectus abdominis (RA)m., quadratus lumborum (QL) m., erector spinae (ES) m., multifidus (MF) m., psoas major (PS) m. and the thickness of obliquus abdominis internus (OAI) m., obliquus abdominis externus (OAE) m. and transversus abdominis (TA) m. were measured. The results of the study revealed that quadratus lumborum (QL) m., erector spinae (ES) m. and multifidus (MF) m. were bigger on the side of a dominant arm. Obliquus abdominis internus (OAI) m. was bigger on the opposite (in relation to the dominant arm) side. No differences were observed in psoas major (PS) m. and transversus abdominis (TA) m. The study confirmed that the cause of back pain in cricket players might be attributed to asymmetric movement technique.

Because muscle effectiveness depends on their volume and training intensity, non-trained abdominal muscles are becoming weakened and extended, which leads to a disturbed equilibrium in lumbosacral part of the vertebral column. Compensation for maintaining balance is provided by excessively developed erector spinae (ES) m. and deepened lordosis [13]. Therefore, on the one hand, there is an ongoing search for the methods of muscle diagnosis and, on the other hand,

the exercises are selected to be suitable for persons threatened with LBP or with its symptoms [14]. Properly developed long-term training schedules strengthen the muscles and ensure improvement in their endurance [15]. MRI imaging confirms that the exercises consisting in sucking in the stomach and flexing the abdominal areas contribute to a considerable increase in the thickness of the transversus abdominis (TA) m., obliquus abdominis externus (OAE) m. and reduction in cross-sectional area of trunk [16]. MAYER et al. [15] measured the activity of the muscles in lumbar part of the vertebral column in 11 healthy persons. They imaged quadratus lumborum (QL) m., iliocostalis lumborum (IL) m., longissimus thoracis (LT) m. and multifidus (MF) m. during rest and after flexing trunk muscles with the intensities of 40%, 50% and 70% of the maximal capacity of the persons examined. As is confirmed based on the analysis of the images obtained, a properly scheduled long-time training of trunk and abdominal muscles results in the strengthening of these muscles and reduces the risk of the occurrence of pain in lower part of the vertebral column.

There have also been other studies which estimated deficiency in MRI method. RANSON et al. [17] verified and compared MRI method and software used for the interpretation of its image in the form of functional cross-sectional areas (part of the muscle after isolating fat tissue). The imaging of cross-sectional areas in trunk muscles is frequently made because of patients suffering from low back pain (LBP). The authors presented the results of their studies using MRI in six subjects in T2 time in sagittal plane in L1–S1. By means of software for analysis of images with grayscale, using intensity of signal radiation different for different tissues, the authors carried out a manual separation and measurement of fat, muscle and bone tissues. Grayscale was employed for calculating functional cross-sectional area (FCSA) in the following muscles: psoas major (PS) m., quadratus lumborum (QL) m., erector spinae (ES) m. and multifidus (MF) m.

Analysis using MRI technique for diagnosis of LBP is very wide. Our study focused on attempts to find the exercises which strengthen muscles stabilizing vertebral column and which do not cause overload in lumbar section of the vertebral column. This will allow for the development of safe exercises, useful not only in back pain prevention but also for the persons with LBP. As results from the study, positions which do not cause excessive pressure in intervertebral discs are adopted when the pressure on joint surfaces in vertebral body is evenly distributed. In practice, this

consists in adjacency to the ground at which the exercise is performed. The application of MRI method for evaluation of cross-sectional areas in the muscles which stabilize vertebral column might provide an assessment of the specific muscle strength (which depends on muscle cross-sectional area). The development of measurement conditions and criteria for strength assessment using MRI method will allow us to evaluate training effects, to show the impact of physical activity on geometric parameters and to develop profiles of younger and older persons. Therefore the goal of this study was to find a position for measurement of cross-sectional areas in the muscles stabilizing vertebral column which allows for performing this function. Moreover, initial measurements among young and older persons will point to the directions of future studies.

2. Material and methods

The study covered two young females, KA and BM (aged 23, $m = 55$ kg, $h = 164$ cm) and two older females, AA and CB (aged 55, $m = 57$ kg, $h = 165$ cm) without LBP symptoms. The investigations were carried out in the Medical Diagnostics Centre Konsylium in Wrocław using SIEMENS Magnetic Harmony Maestro Class 1T equipment for magnetic resonance imaging. The subjects examined were asked to lie on the back on the movable table of the device, with upper limbs straight along the body and with lower extremities straight. Next, the technician, using special-purpose belts, fastened the patients to the table and moved them to the tunnel of the MRI scanner. Two measurements were taken for different positions of the persons examined. Each test was taken exhaled while the subjects were lying motionless. During the first measurement, the persons were lying on the back in anatomical position (AP), whereas during the second measurement they pulled the chin to the sternum (HP – head position) (figure 1). All the persons gave their written consent for the experiment. The investigations were accepted by the Bioethical Commission.

By means of NUMERIS 14 software, version synagro MR A30, cross-sectional areas (CSAs) and brightness (B) on the right and left sides were measured and calculated in the following muscles (figure 2): rectus abdominis (RA) m., anterolateral abdominal (IABD) mm., psoas major (PS) m., quadratus lumborum (QL) m., lumbar erector spinae (ES) m. and multifidus (MF) m. The muscle group of anterolateral

abdominal (IABD) includes three muscles: transversus abdominis (TA) m., obliquus abdominis internus (OAI) m. and obliquus abdominis externus (OAE) m. They could not be separated in MRI image so that their cross-sectional areas were measured separately. Thus, the total area was calculated (IABD), and then the brightness (B) was measured for each of them.

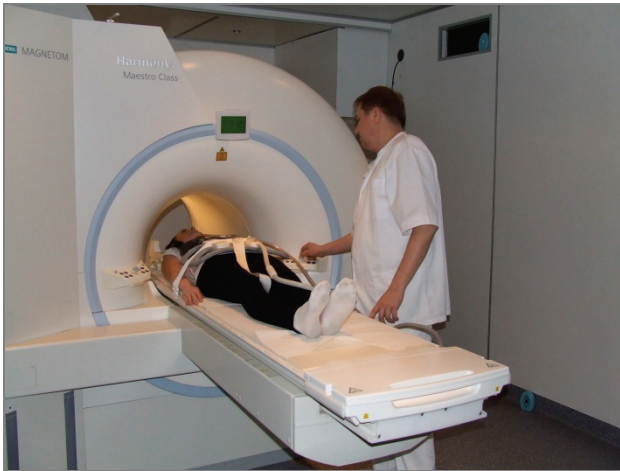

Fig. 1. Measuring stand – MRI

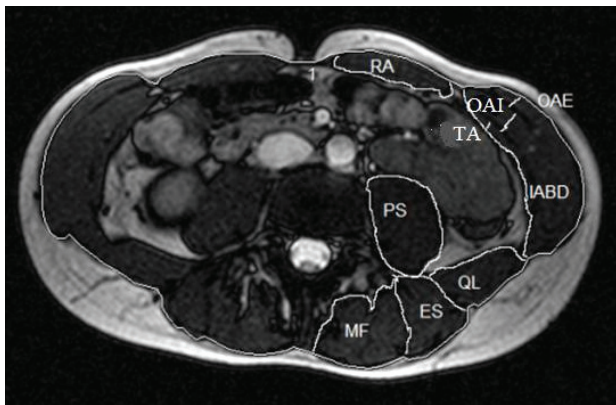


Fig. 2. Cross-section of trunk in MRI image for the layer parallel to the intervertebral disc at a height of L3/L4 with the marked muscles of the left side of the body. Abbreviations were explained in the text

Each type of tissue (depending on its chemical composition) shows specific (shorter or longer) relaxation time (due to restoring to the state before activation), which is the source of the signal with low intensity (visible in the computer screen with wide grayscale). Relaxation occurs in hydrogen atoms (hydrogen is the main constituent of water): tissues with higher content of water are very bright, whereas those with its low content are dark. Therefore, bones are almost “invisible”, while the tissues typical of muscles, ligaments, tendons and internal body organs are recognized with slightly different shades of gray.

3. Results

3.1. Measuring position and geometrical parameters of muscles

The following parameters were compared in the study: cross-sectional area (CSA), thickness (T) and brightness (B) in the above-mentioned muscles which constitute muscular corset for the vertebral column on the left and right sides of four persons, in anatomical position (AP) and head position (HP). It was assumed that higher values of cross-sectional area and muscle thickness testified to higher specific strength [6], and thus better stabilization function of these muscles. Lower brightness in muscles corresponds to lower content of fat tissue and higher content of muscle tissue.

3.1.1. Cross-sectional area of muscles

Forced activity in the muscles stabilizing vertebral column causes rise in their cross-sectional area. Rising head and pulling it to the sternum while lying on the back were supposed to activate muscles which stabilize vertebral column to a higher degree than in anatomical position. In order to achieve this, measurements of cross-sectional areas (CSAs, figures 3–6) and thickness (T, figures 7–10) were taken in the persons examined in two positions: anatomical position (AP) and the head pulled to the sternum (HP).

In the case of rectus abdominis (RA) m. and the muscle complex referred to as anterolateral abdominal (IABD) m., change in position did not increase muscle cross-sectional area. In some persons, this parameter remained unchanged, whereas in the others, it was insignificantly reduced or increased. Pulling head to chest resulted in an insignificant rise in cross-sectional area in quadratus lumborum (QL) m. in two persons (figures 4 and 6).

Change in positions caused rise in the cross-sectional area in erector spinae (ES) m. in all the subjects examined. Psoas major (PS) m. in three studied persons also caused rise in its cross-sectional area after change in position. Multifidus (MF) m. showed clear rise in cross-sectional area only in the person BM, whereas in other persons, the position with pulled head did not result in changes in CSA of the muscle.

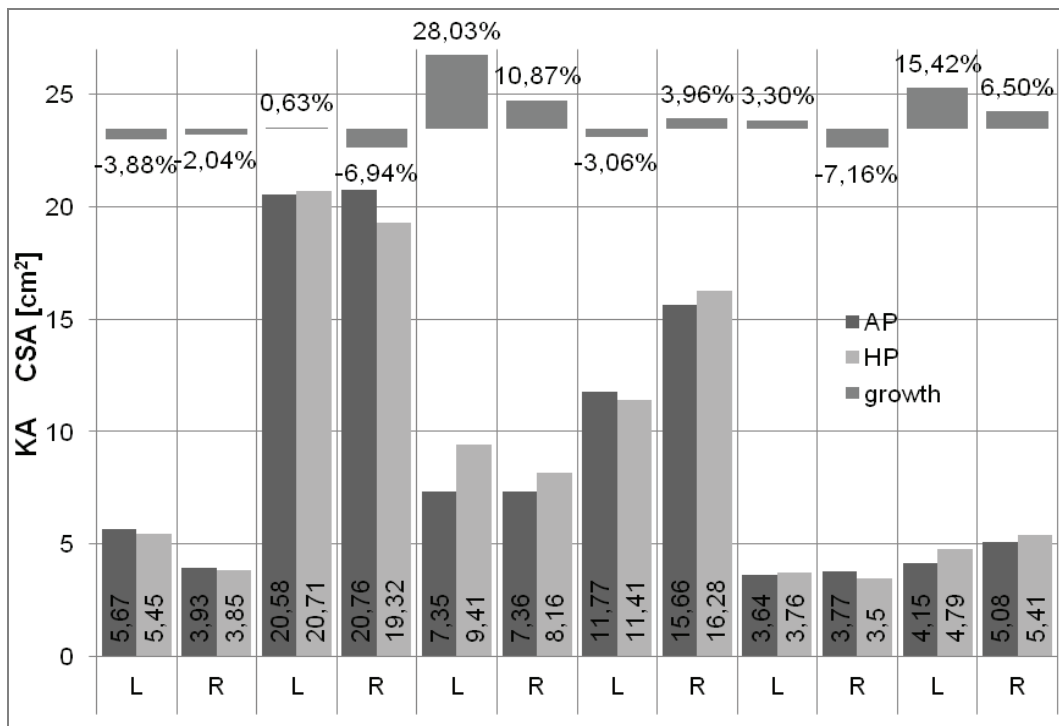


Fig. 3. Cross-sectional area CSA (cm²) of muscles in KA person in anatomical (AP) and head (HP) positions

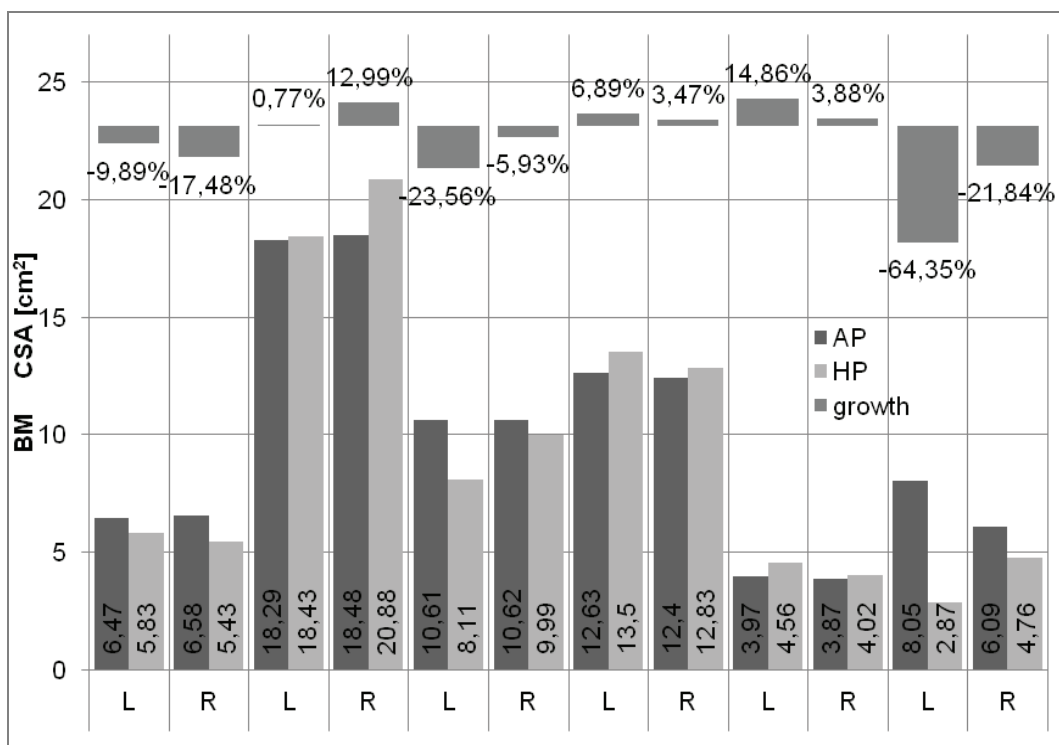


Fig. 4. Cross-sectional area CSA (cm²) of muscles in BM person in anatomical (AP) and head (HP) positions

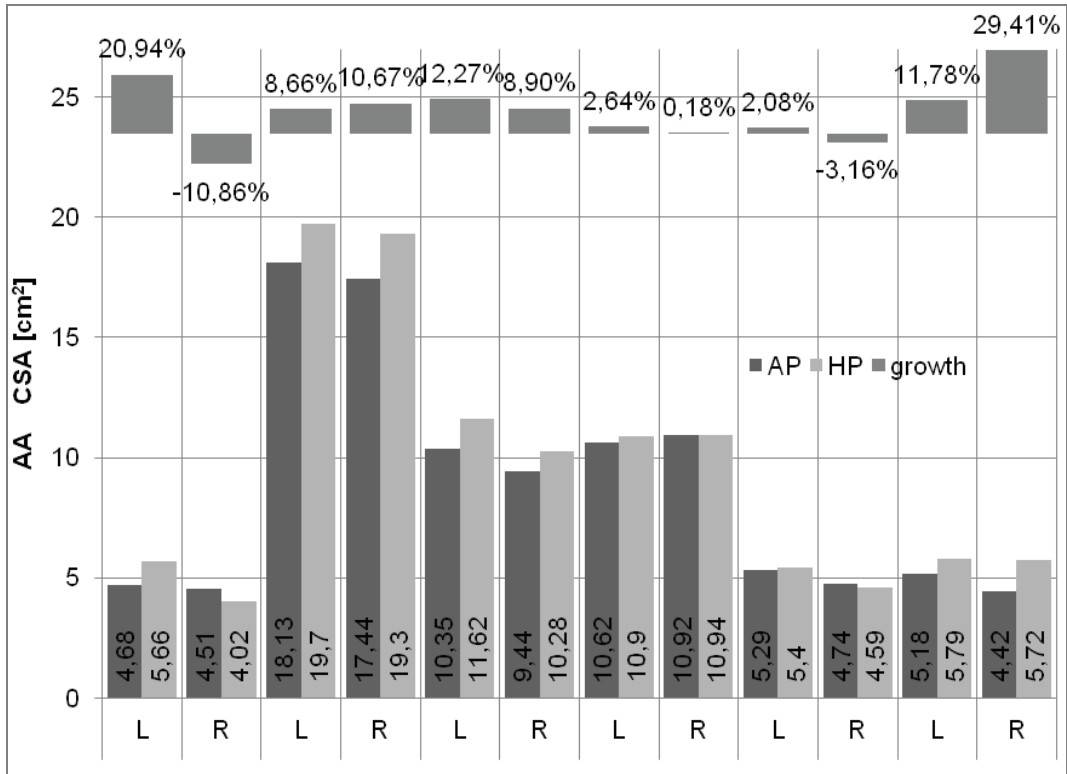


Fig. 5. Cross-sectional area CSA (cm²) of muscles in AA person in anatomical (AP) and head (HP) positions

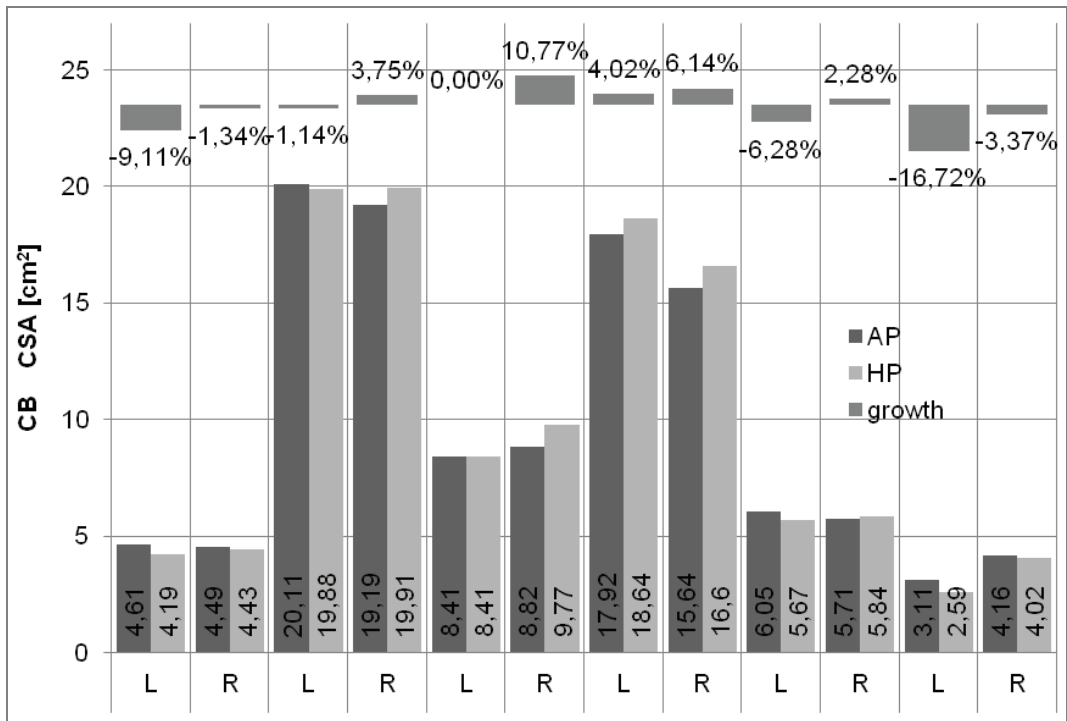


Fig. 6. Cross-sectional area CSA (cm²) of muscles in CB person in anatomical (AP) and head (HP) positions

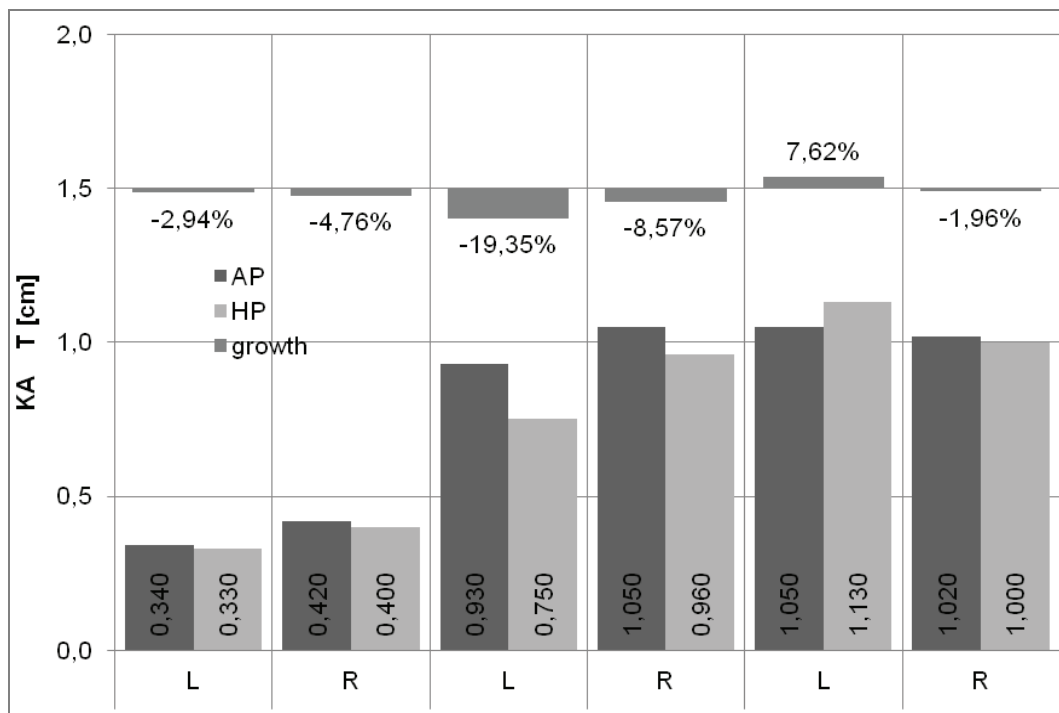


Fig. 7. Thickness T (cm) of muscles in KA person in anatomical (AP) and head (HP) positions

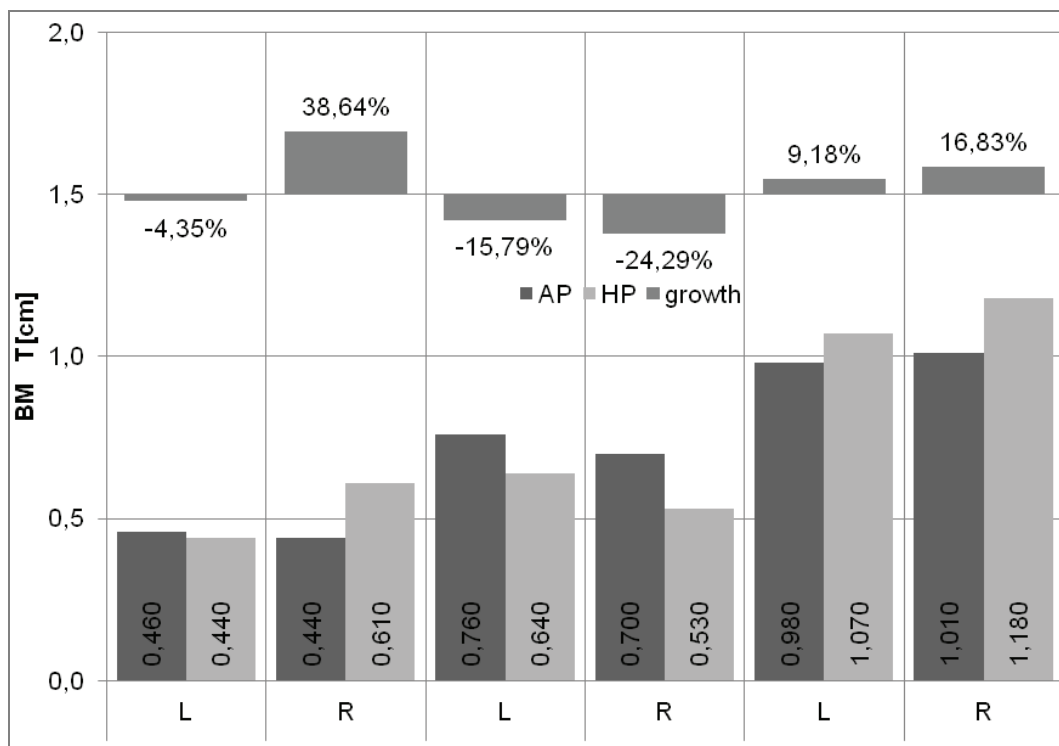


Fig. 8. Thickness T (cm) of muscles in BM person in anatomical (AP) and head (HP) positions

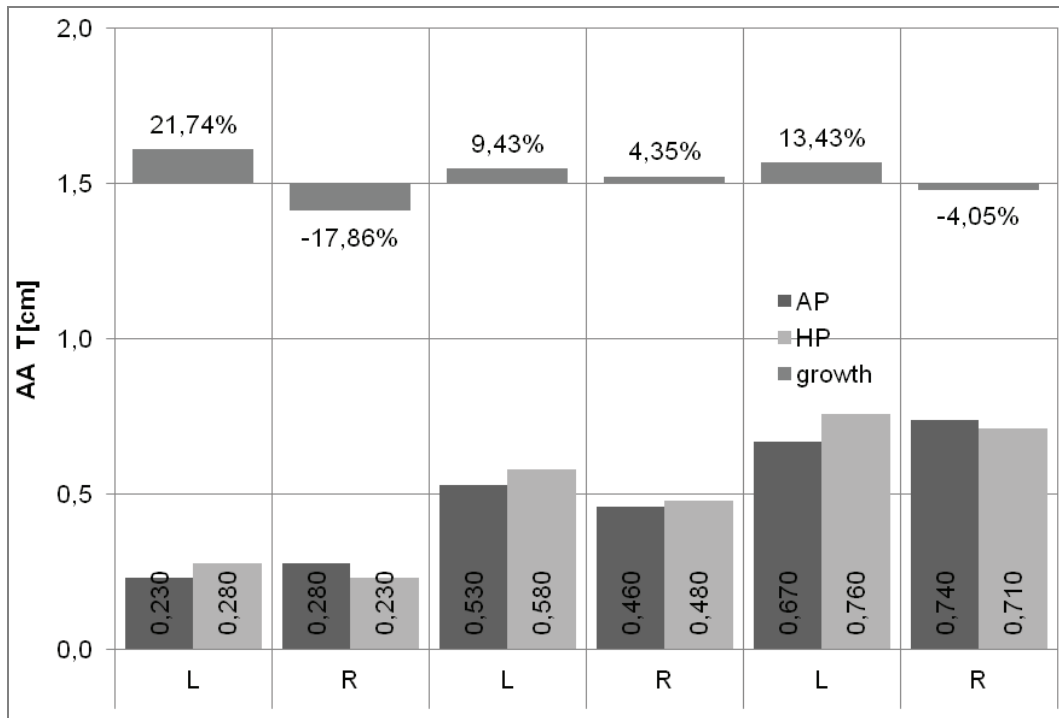


Fig. 9. Thickness T (cm) of muscles in AA person in anatomical (AP) and head (HP) positions

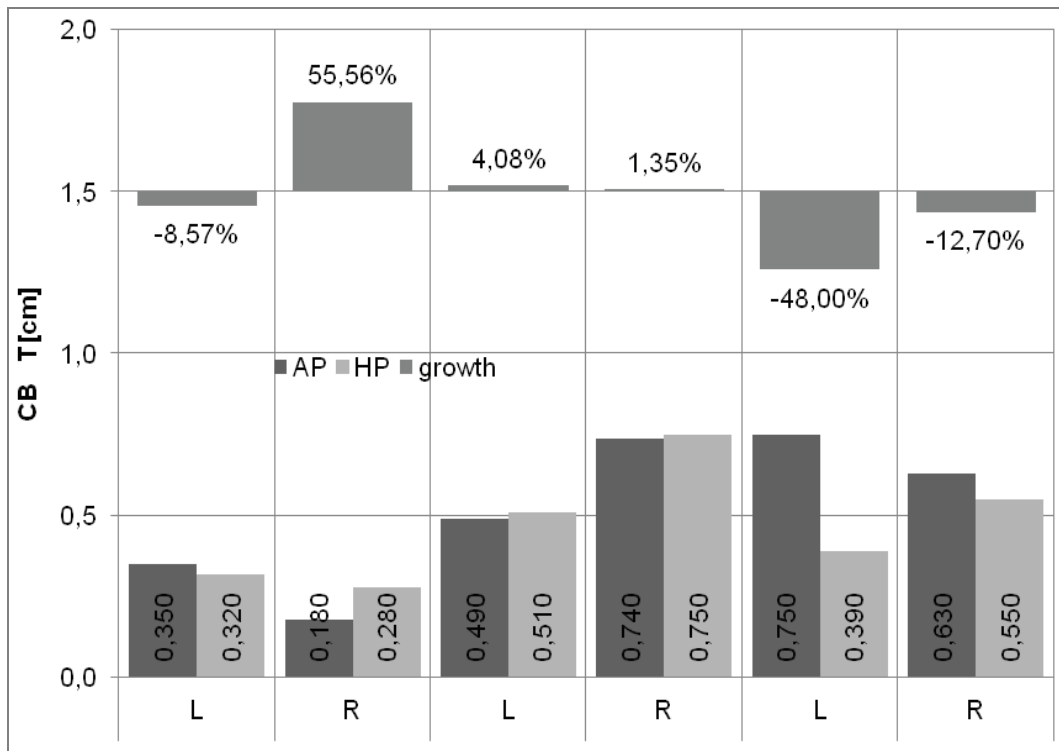


Fig. 10. Thickness T (cm) of muscles in CB person in anatomical (AP) and head (HP) positions

3.1.2. Thickness of muscles

Change from anatomical position (AP) to head position (HP) did not result in changes of muscle thickness in transversus abdominis (TA) m. in the person KA. In other persons, rise in muscle thickness observed on one side was accompanied by the reduction in its thickness on the other side.

Obliquus abdominis internus (OAI) m., after change in position, did not show any changes in older persons, whereas in young persons, the reduction in its thickness was observed. Change in the position in obliquus abdominis externus (OAE) m. resulted either in rise (person BM) or did not cause any changes in thickness (KA, AA). In the case of the person CB, a reduction in the thickness was observed.

3.2. Age of persons and geometrical parameters of their muscles

The muscle fibres have decreased in number with age. The reduction in muscle mass is one of the symptoms of ageing. In the present study, geometrical parameters of muscles in young and older persons in anatomical position were examined.

3.2.1. Muscle cross-sectional area (CSA)

A larger muscle cross-sectional area (CSA) in rectus abdominis (RA) m. was observed in young persons. No differences were reported in cross-sectional areas in IABD, ES, PS, and QL mm. Erector spinae (ES) m. was the smallest in an older person (AA), the largest also in an older person (CB). Multifidus (MF) m. was smaller in younger persons.

3.2.2. Thickness of muscles

The thickness of transversus abdominis (TA) m., obliquus abdominis internus (OAI) m., obliquus abdominis externus (OAE) m. was considerably higher in young persons.

3.2.3. Brightness

Brighter fields in MRI image provide information about the amount of water contained in the fibres examined. Mean brightness calculated for the persons examined (figure 11) was lower in those who were physically active (KA and AA), which might point to lower content of fat tissue in their muscles.

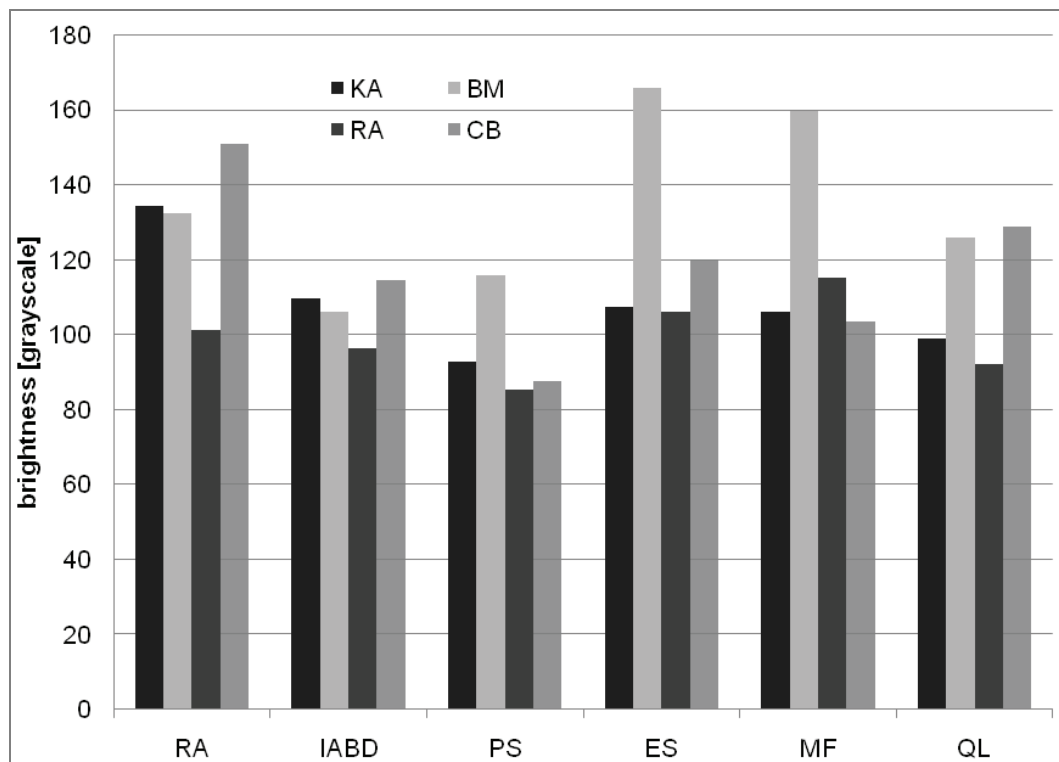


Fig. 11. Mean muscle brightness B (gray scale)

4. Discussion

The activity of rectus abdominis (RA) m. on both sides consists in bending trunk forward in order to, e.g., lift upper part from lying on the back. In our experiment, this function was excluded through straightening and stabilization of lower extremities. Bending the upper body, this muscle causes that ribs are lowered, thus it performs the role of a respiratory muscle. Another fact is that it affects the statics of content of abdominal cavity and strengthens abdominal prelum. Rectus abdominis (RA) m. is the strongest antagonist of erector spinae (ES) m. [18]. In both muscles in a young person (KA), who trained fencing, the asymmetry between left and right sides in these muscles was observed. ES was larger on the right side, whereas RA on the opposite one (left). HP position caused, in all the persons examined, a rise in cross-sectional area of ES muscle, whereas in the case of RA no differences were observed.

Obliquus abdominis externus (OAE) m., while contracting, bends the vertebral column and thorax to the side and turns the trunk to the other side. Bilateral contraction bends the vertebral column forwards and pulls the thorax down. Therefore, it is also an active respiratory muscle [18]. Young people typically show greater thickness of this muscle.

While contracting, quadratus lumborum (QL) m. bends the trunk laterally to the side and, whereas in the muscle tone state, it fixes a lumbar part of the vertebral column. In the case of paralysis, it causes scoliosis in a lumbar part. Bilateral contraction lowers the twelfth rib [18]. The asymmetry in the dimensions of cross-sectional areas in this muscle may cause LBP. This asymmetry can be observed in all the persons examined.

With fixed lower extremities or in the position of lying on the back, psoas major (PS) m., during lifting the trunk, co-acts with rectus abdominis m. and also affects lumbar part of the vertebral column. While contracting bilaterally, it bends the vertebral column forwards [18]. Psoas major (PS) m. increased its cross-sectional area in all the persons examined.

While contracting bilaterally, multifidus (MF) m. straightens the vertebral column and fixes it, whereas it laterally bends spine to the side and turns the column to the other side [18]. It is characterized by the smallest cross-sectional area in young persons.

The present study revealed that young persons demonstrated greater cross-sectional areas of rectus abdominis (RA) m., transversus abdominis (TA) m. and obliquus abdominis externus (OAE) m. and

smaller area of multifidus (MF) m. than older females. The cross-sectional areas of psoas major (PS) m., quadratus lumborum (QL) m. and erector spinae (ES) m. in all the women were comparable. The reasons for the difference in the structure of muscles between young and older persons were explained in the studies by DOHERTY [19] and FULLE et al. [20]. They argued that sarcopenia, i.e. reduction in muscle mass with a simultaneous reduction in the muscle strength, is one of the symptoms associated with ageing. In the studies on condition of skeletal muscles in subjects aged between 18 and 88, JANSSEN et al. [21] examined 468 persons. One of the conclusions was that reduction in skeletal muscle mass, beginning around human early thirties, is insignificant until 50, and then this process intensifies. The conclusion might provide an explanation for the differences in cross-sectional areas between young and older persons examined in the present study.

5. Final results

Muscles stabilize the vertebral column function usually in an upright standing position; however, MRI examination cannot be carried out in this arrangement. Measurements of geometrical parameters in the positions studied were carried out after ensuring uniform conditions for all the subjects examined. Position with head pulled to thorax should force higher isometric contraction. The measurements show that other conditions of the experiments cause neither increase in cross-sectional area nor increase in thickness. The differences in geometrical parameters of the muscles examined prove different coordination of muscle activation in the persons examined, both young and older. The discrepancies in the sizes and brightness of the muscles (between young and older persons) point to the purposefulness of continuing this type of measurements.

Acknowledgements

The study was carried out within KBN project No. N N404 155 834.

References

- [1] BORENSTEIN D.G., *Epidemiology, etiology, diagnostic evaluation and treatment of low back pain*, Current Opinion in Orthopaedics, 2000, 11 (3), 225–231.
- [2] KJAER P., LEBOEUF Y.CH., KORSHOLM L., SORENSEN J.S., BENDIX T., *Magnetic resonance imaging and low back pain in adults: A diagnostic imaging study of 40-year-old men and women*, Spine, 2005, 30, 1173–1180.

- [3] WEJSFLOG G., *Etiopatogeneza i patomechanika dystonicznych bocznych skrzywień kręgosłupa*, Chirurgia Narządu Ruchu, 1956, 21, 54, [w:] Tylman D., *Patomechanika bocznych skrzywień kręgosłupa*, Warszawa 1995, s. 3.
- [4] NORRIS C.M., *Functional load abdominal training: part 1*, Journal of Bodywork and Movement Therapies, 1999, 3(3), 150–158.
- [5] CONLEY M.S., MEYER R.A., BLOOMBERG J.J., FEEDBACK D.L., DUDLEY G.A., *Noninvasive analysis of human neck muscle function*, Spine, 1995, 20(23), 2505–2512.
- [6] BOBER T., ZAWADZKI J., *Biomechanika układu ruchu człowieka*, Wydawnictwo BK, 2001, citing McDonagh M.J.N., Davies C.T.M., *Adaptive response of mammalian skeletal muscle to exercise with high loads*, European Journal of Applied Physiology, 1984, 52 (2), 139–155.
- [7] WOOD S., PEARSALL D.J., ROSS R., REID J.G., *Trunk muscle parameters determined from MRI for lean to obese males*, Clinical Biomechanics, 1996, 11 (3), 139–144.
- [8] GZIK M., WOLAŃSKI W., TEJSZERSKA D., *Experimental determination of cervical spine mechanical properties*, Acta of Bioengineering and Biomechanics, 2008, 10 (4), 49–54.
- [9] HIDES J. A., RICHARDSON J.A., GWENDOLEN C.A., JULL A., *Magnetic resonance imaging and ultrasonography of the lumbar multifidus muscle. Comparison of two different modalities*, Spine, 1995, 20 (1), 54–58.
- [10] MOONEY V., GULICK J., PERLMAN M., LEVY D., POZOS R., LEGGETT S., RESNICK D., *Relationships between myoelectric activity, strength, and MRI of the lumbar extensor muscles in back pain patients and normal subjects*, Journal of Spinal Disorders, 1997, 10, 348–56.
- [11] MARRAS W.S., JORGENSEN M.J., GRANATA K.P., WIAND B., *Female and male trunk geometry: size and prediction of the spine loading trunk muscles derived from MRI*, Clinical Biomechanics, 2001, 16, 38–46.
- [12] HIDES J.A., STANTON W., FREKE M., WILSON S., McMAHON S., RICHARDSON C., *MRI study of the size, symmetry and function of the trunk muscles among elite cricketers with and without low back pain*, British Journal of Sports Medicine, 2008, 42, 809–813.
- [13] GZIK M., *Biomechanika kręgosłupa człowieka*, Wydawnictwo Politechniki Śląskiej, Gliwice, 2007, 43–57.
- [14] RUTKOWSKA-KUCHARSKA A., SZPALA A., PIECIUK E., *Symmetry of muscle activity during abdominal exercises*, Acta of Bioengineering and Biomechanics, 2009, 11 (1), 25–30.
- [15] MAYER M.J., GRAVES J.E., CLARK B.C., FORMIKELL M., PLOUTZ-SNYDER L.L., *The use of magnetic resonance imaging to evaluate lumbar muscle activity during trunk extension exercise at varying intensities*, Spine, 2005, 30, 2556–2563.
- [16] HIDES J., WILSON S., STANTON W., McMAHON S., KETO H., McMAHON K., BRYANT M., RICHARDSON C., *An MRI investigation into the function of the transversus abdominis muscle during “drawing-in” of the abdominal wall*, Spine, 2006, 31 (6), E175–E178.
- [17] RANSON C.A., BURNETT A.F., KERSLAKE R., BATT M.A., O’SULLIVAN P.B., *An investigation into the use of MR imaging to determine the functional cross sectional area of lumbar paraspinal muscles*, European Spine Journal, 2006, 15, 764–773.
- [18] BOCHENEK A., *Anatomia Człowieka*, t. I, PZWL, Warszawa, 1990, 668–714.
- [19] DOHERTY T.J., *Invited review: Aging and sarcopenia*, J. Appl. Physiol., 2003, 95, 1717–1727.
- [20] FULLE S., PROTASI F., Di TANO G., *The contribution of reactive oxygen species to sarcopenia and muscle ageing*, Exp. Gerontol., 2004, 39, 17–24.
- [21] JANSSEN I., HEYMSFIELD S.B., WANG Z.M., ROSS R., *Skeletal muscle mass and distribution in 468 men and women aged 18–88 yr.*, J. Appl. Physiol., 2000, 89, 81–88.